

A few questions on the content of the
previous lecture

slido



Electrical synapses work via ..., and are mostly

ⓘ Start presenting to display the poll results on this slide.

slido



**Receptors of chemical synapses can be categorized as:
... and ...(choose all that apply)**

ⓘ Start presenting to display the poll results on this slide.

slido



Neurotransmitters fall into two main categories: ... and ...

ⓘ Start presenting to display the poll results on this slide.

Any questions/remarks before we begin
today's lecture?



Nervous system development

Dr. Lavinia Carmen Uscătescu

November 13th 2023

Outline

1. Orientation and section planes
2. Surface neuroanatomy
3. Embryology

Orientation and section planes

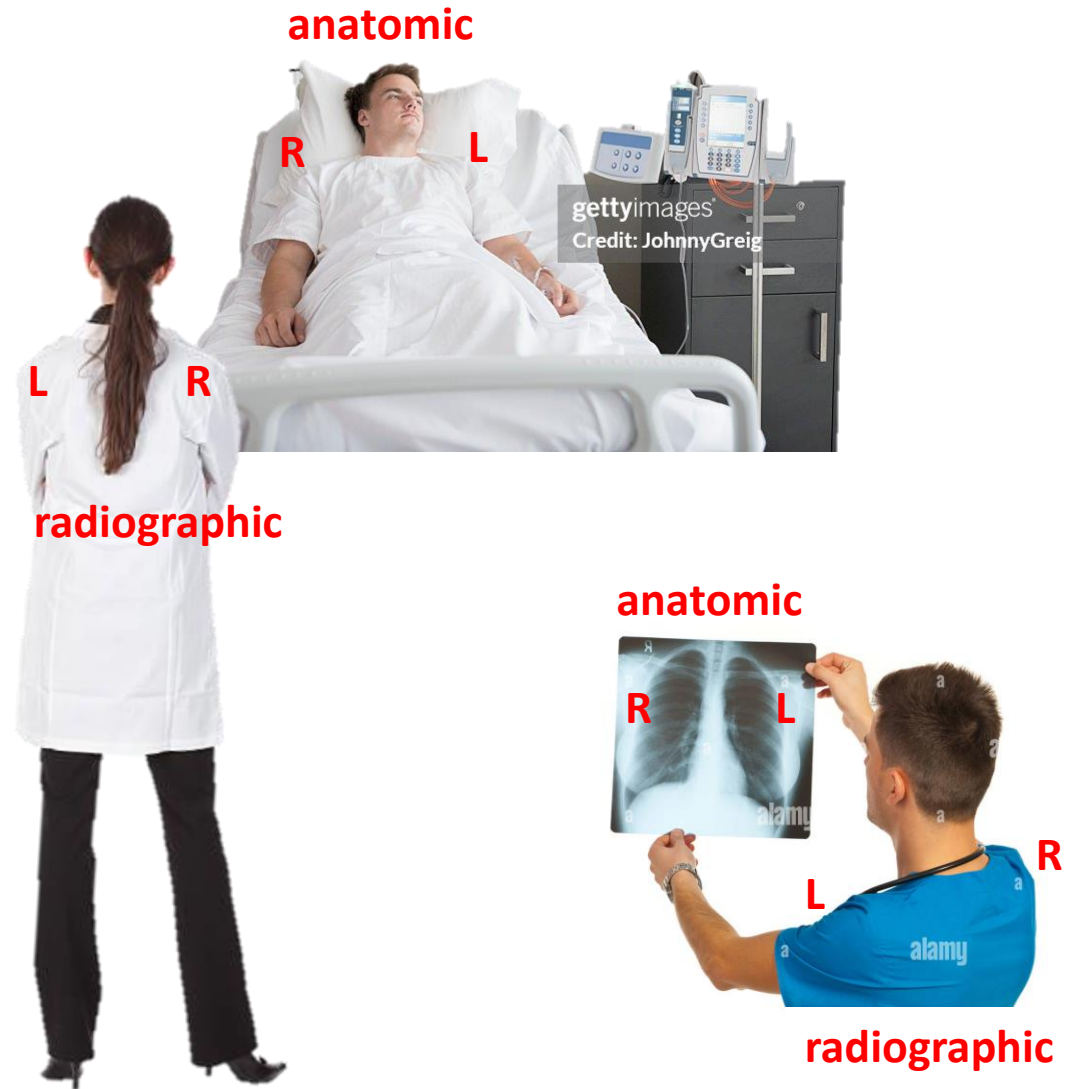
The radiologic v. anatomic convention

radiographic left/L or right/R

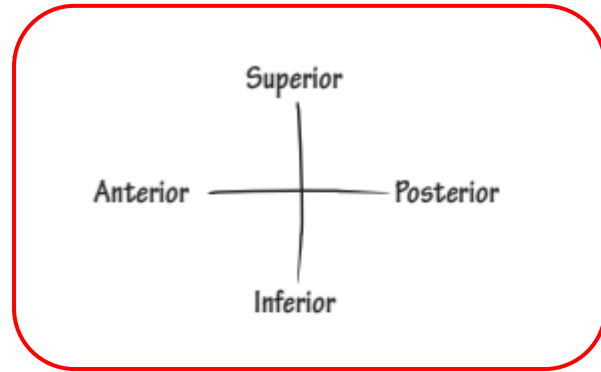
reflects the **viewpoint of a radiologist** inspecting a **radiograph**, or of a doctor standing at the foot of the patient's bed

anatomic left/L or right/R

reflects the **viewpoint of the patient**



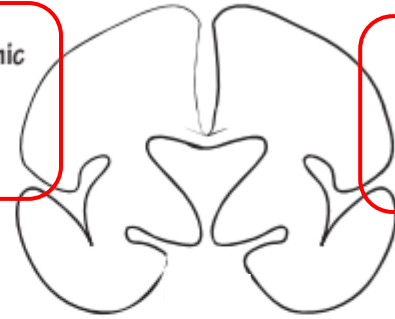
Orientation



this tells us that we are looking at this slice from behind (from the back of the head)

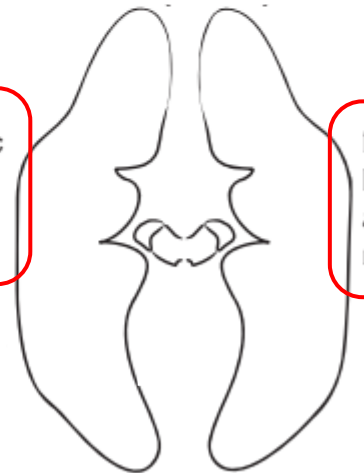
Radiographic right & anatomic left

Radiographic left & anatomic right



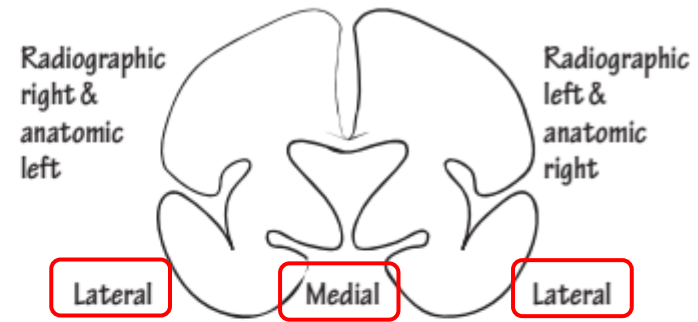
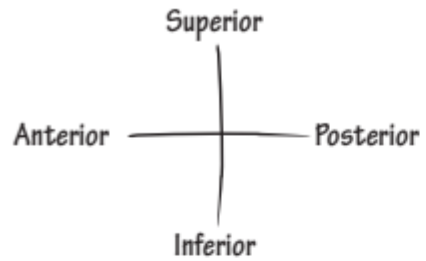
Radiographic right & anatomic left

Radiographic left & anatomic right



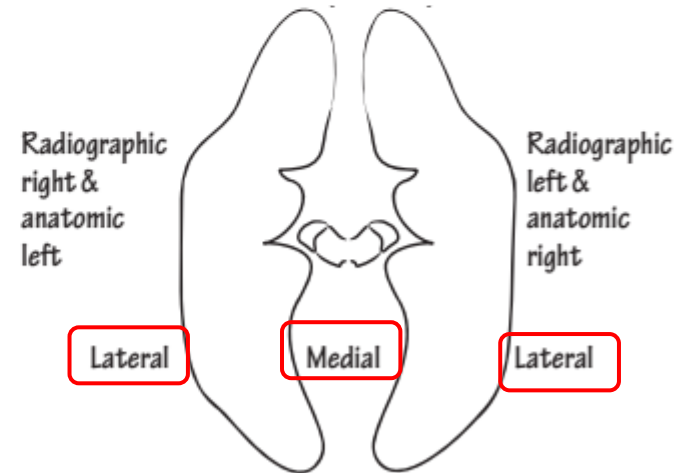
DRAWING 1-2 **Orientational Terminology**

Fisch, (2012), p. 7



e.g., **medial** prefrontal cortex

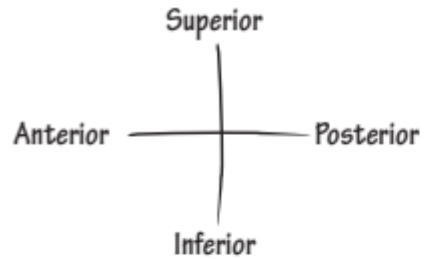
illustrate using <https://neuroquery.org/>



DRAWING 1-2 Orientational Terminology

Fisch, (2012), p. 7

(a) forebrain



rostral

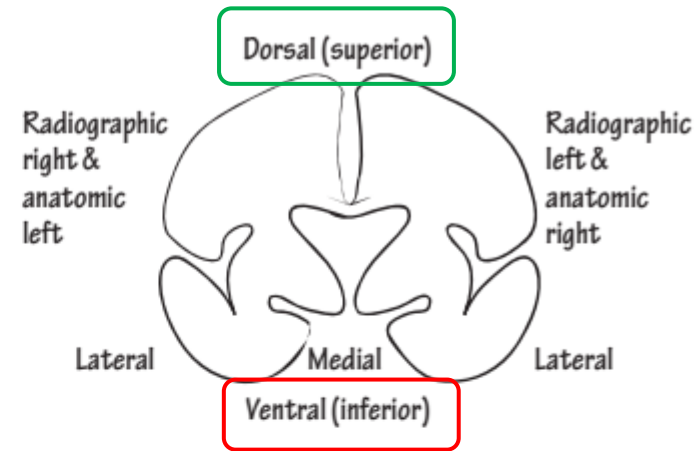
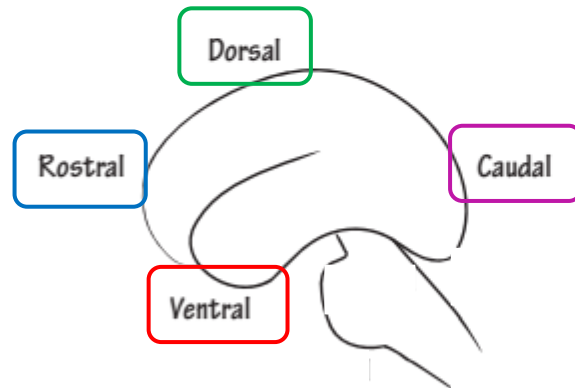
from Latin (rostrum):

"animal snout or bird's beak"

caudal

from Latin (cauda):

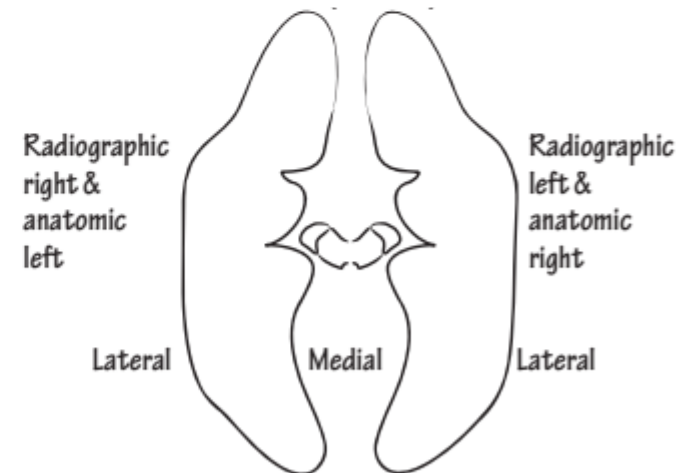
"tail of an animal"



dorsal

from Latin (dorsualis)

"of or pertaining to the back"



ventral

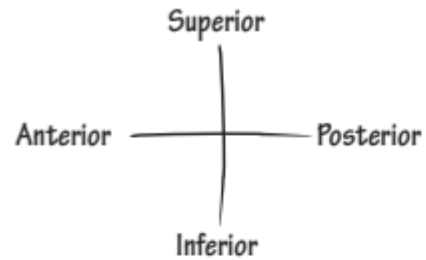
from Latin (ventralis)

"of or pertaining to the belly or stomach"

DRAWING 1-2 Orientational Terminology

Fisch, (2012), p. 7

(b) brain stem and spinal cord



rostrum

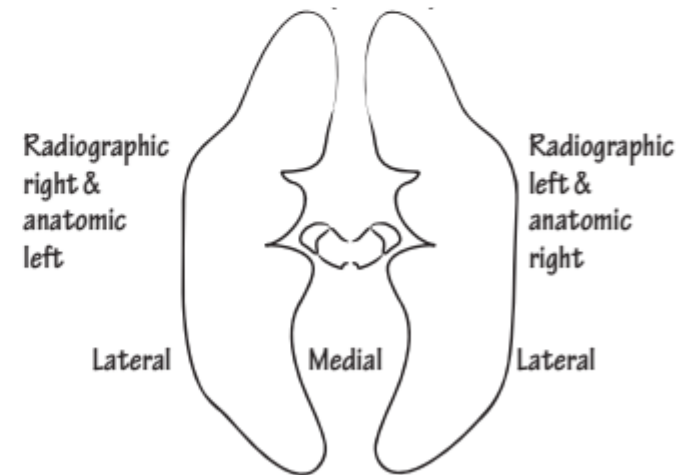
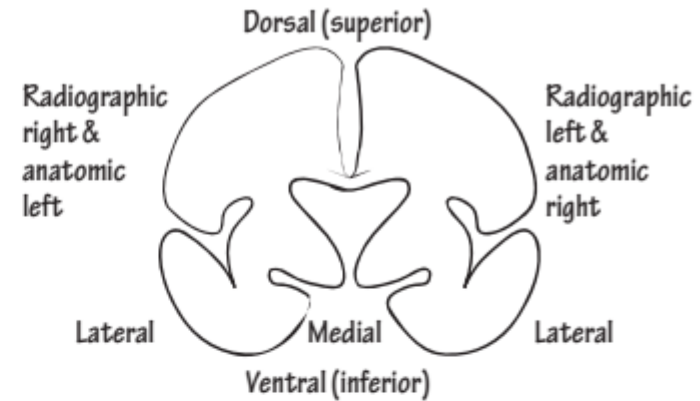
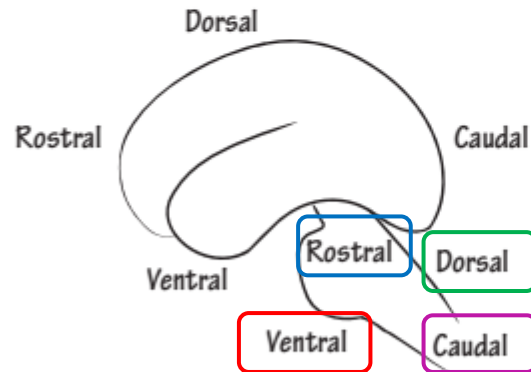
from Latin:

"animal snout or bird's beak"

cauda

from Latin:

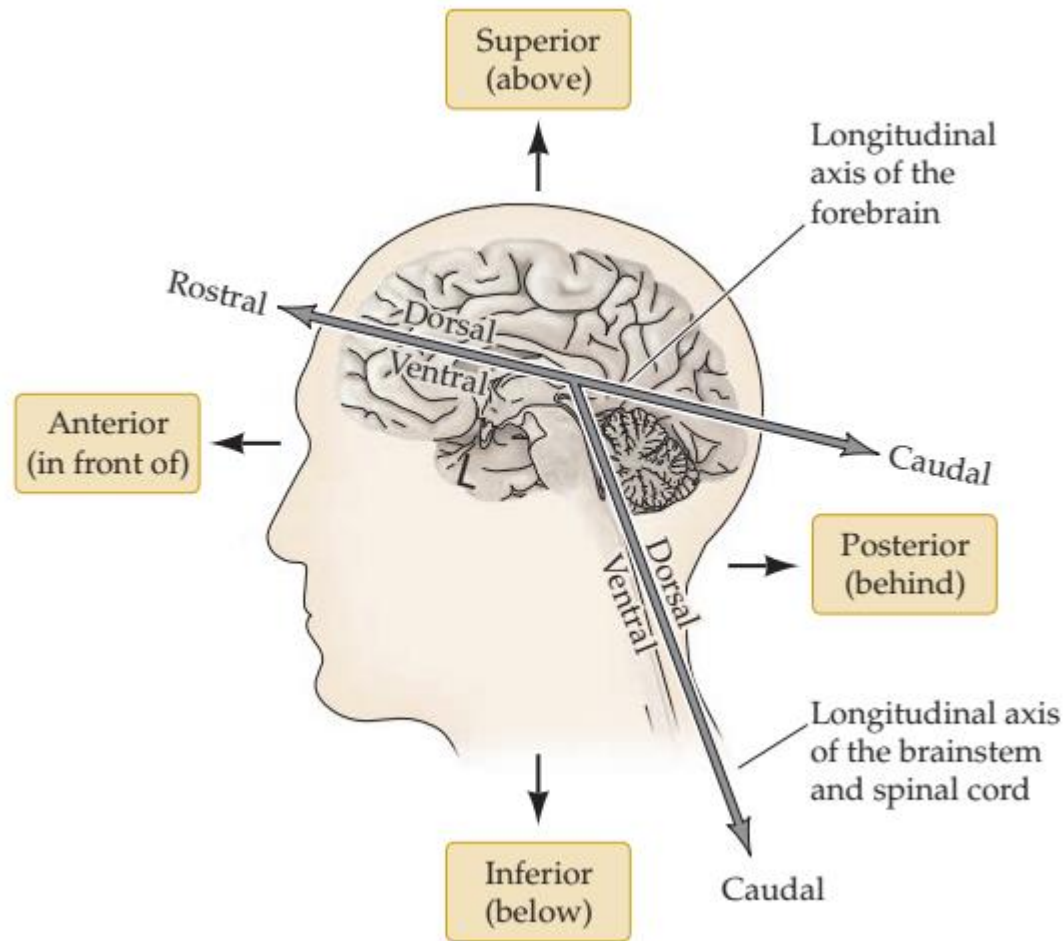
"tail of an animal"



DRAWING 1-2 Orientational Terminology

Fisch, (2012), p. 7

Orientation of the forebrain v. brain stem and spinal cord



Purves et al., (2018), Appendix

A flexure in the long axis of the nervous system arose as humans evolved **upright posture**, leading to an $\sim 120^\circ$ angle between the long axis of the brainstem and that of the forebrain
=> consequences for anatomical terminology.

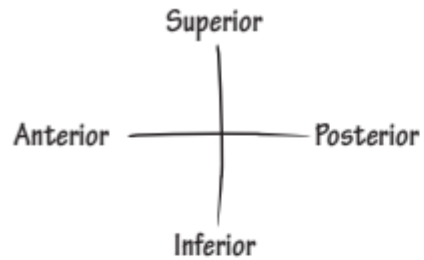
The terms **anterior, posterior, superior, and inferior** refer to the **long axis of the body**, which is straight. Therefore, these terms indicate the same direction for both the forebrain and the brainstem.

In contrast, the terms **dorsal, ventral, rostral, and caudal** refer to the **long axis of the CNS.**

The **dorsal** direction is **toward the back** for the brainstem and spinal cord, **but toward the top of the head** for the forebrain. The opposite direction is ventral.

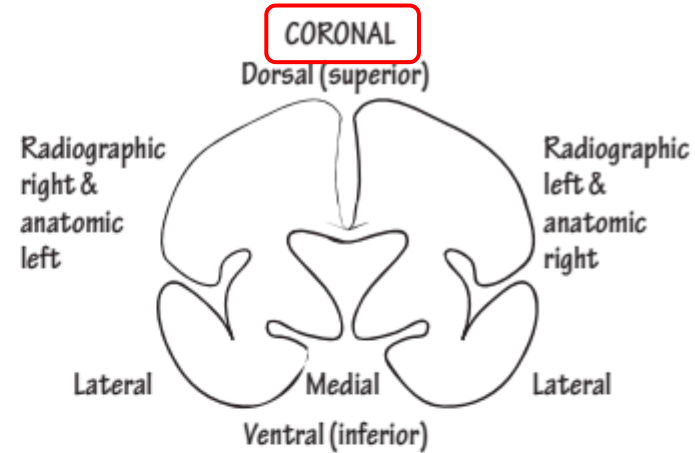
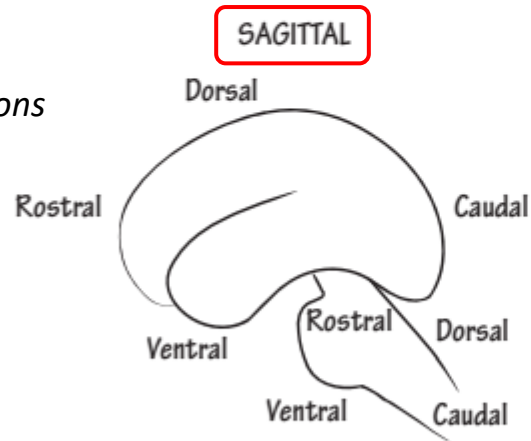
The **rostral** direction is **toward the top of the head** for the brainstem and spinal cord, **but toward the face** for the forebrain. The opposite direction is caudal.

Section planes



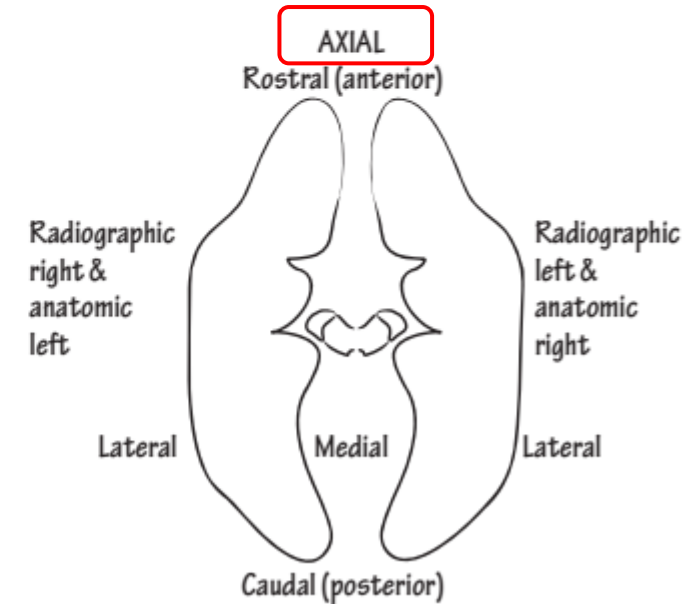
sagittal

the longitudinal plane dividing our body into **right** and **left** sections
from Latin (*sagitta*): “arrow”



coronal

the vertical plane dividing our body into **rostral** and **caudal** sections
from Latin (*coronalis*):
“of or pertaining to a crown”



axial

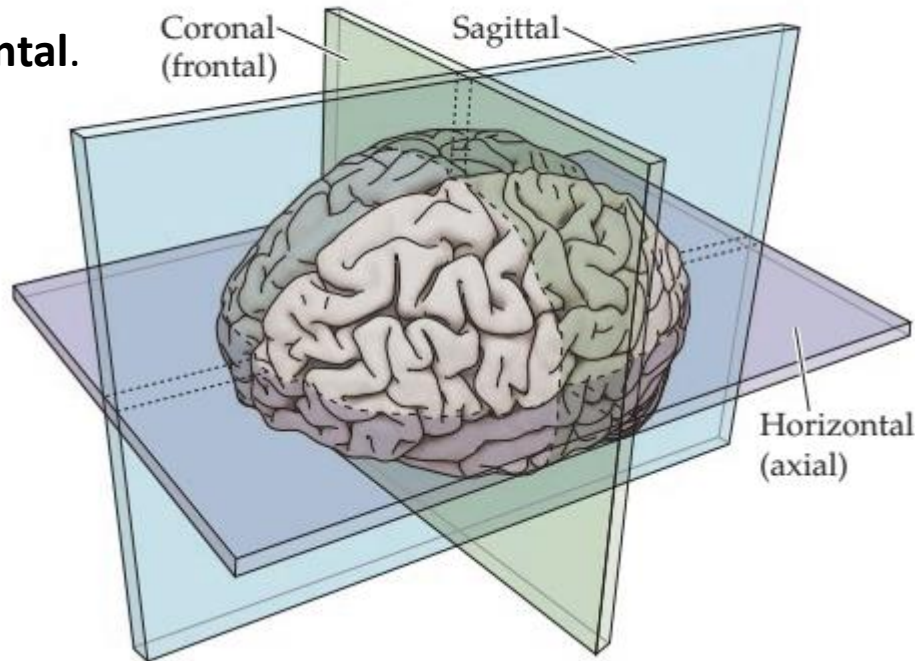
the horizontal plane dividing our body into **ventral** and **dorsal** sections

DRAWING 1-2 Orientational Terminology

Fisch, (2012), p. 7

Sections taken in the plane **dividing the two hemispheres** are **sagittal** and can be further categorized as **midsagittal** or **parasagittal**, according to whether the section is at the midline (midsagittal) or is more lateral (parasagittal).

Sections in the plane of the **face** are called **coronal** or **frontal**.

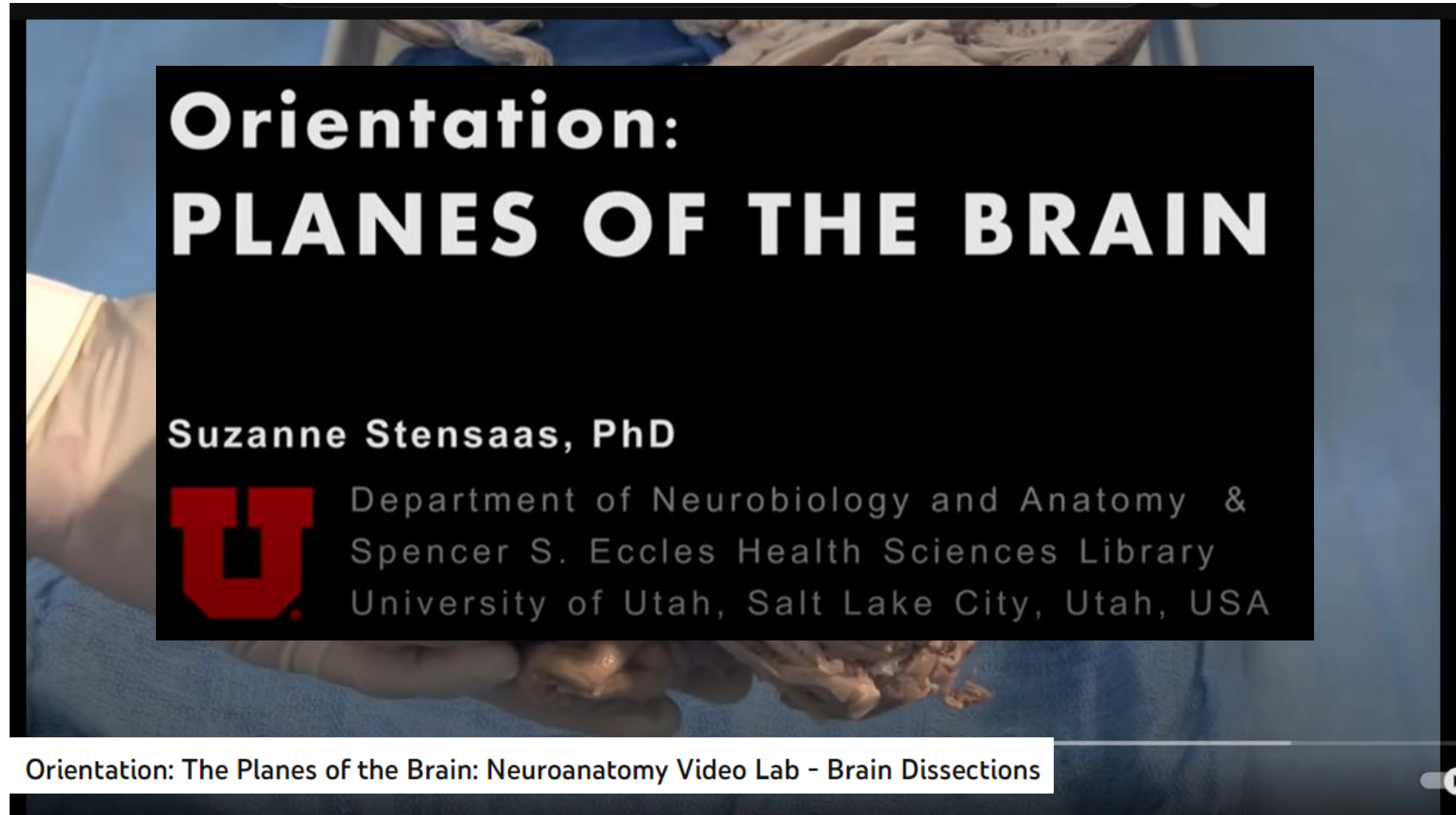


Horizontal/ axial sections are taken **parallel to the rostral–caudal axis of the brain** => parallel to the ground in an individual standing upright.

Purves et al., (2018), Appendix


The plane of section orthogonal (perpendicular) to the long axis of the brainstem and spinal cord is the **transverse**, whereas sections parallel to this axis are **longitudinal**.

Let's see all this in 3D



Orientation: PLANES OF THE BRAIN

Suzanne Stensaas, PhD

 Department of Neurobiology and Anatomy &
Spencer S. Eccles Health Sciences Library
University of Utah, Salt Lake City, Utah, USA

Orientation: The Planes of the Brain: Neuroanatomy Video Lab - Brain Dissections

https://www.youtube.com/watch?v=f_hxX_xvHQY from minute 3:06

Surface neuroanatomy

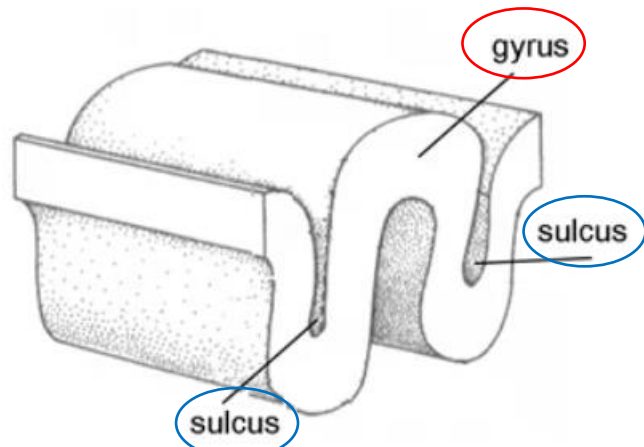
Major landmarks and structures

gyrus, (pl.) gyri

convolution between grooves of the brain

from Latin (*gyrus*): "circle"

from Greek (*gyros*): "ring, circle"

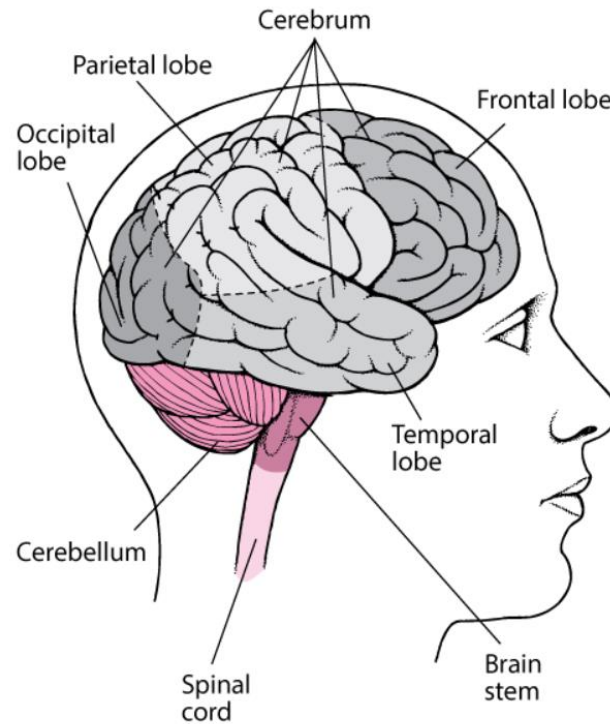


<https://tinyurl.com/56h9byp6>

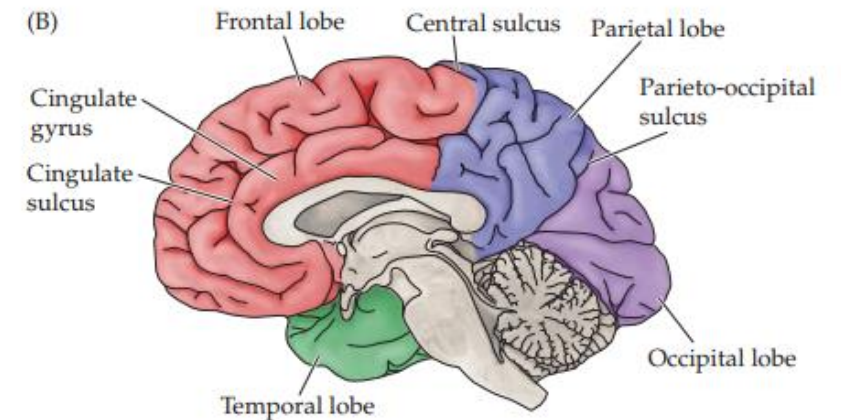
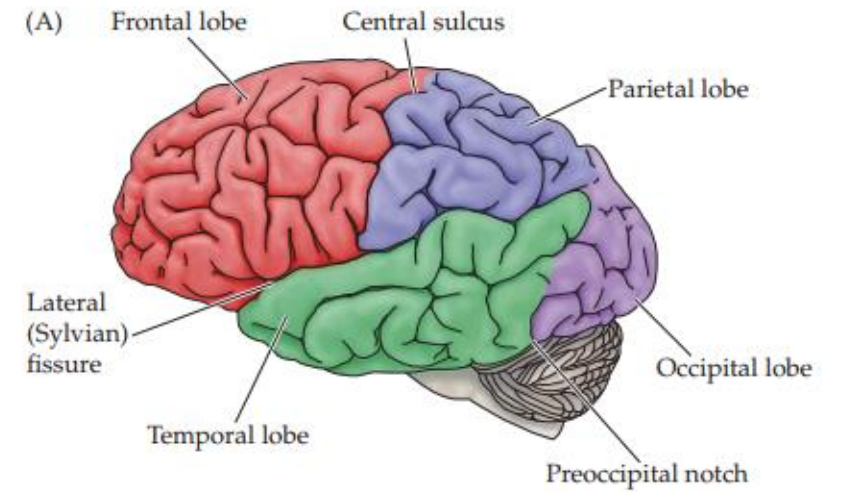
sulcus, (pl.) sulci

fissure between convolutions of the brain

from Latin (*sulcus*): "furrow, trench, ditch"

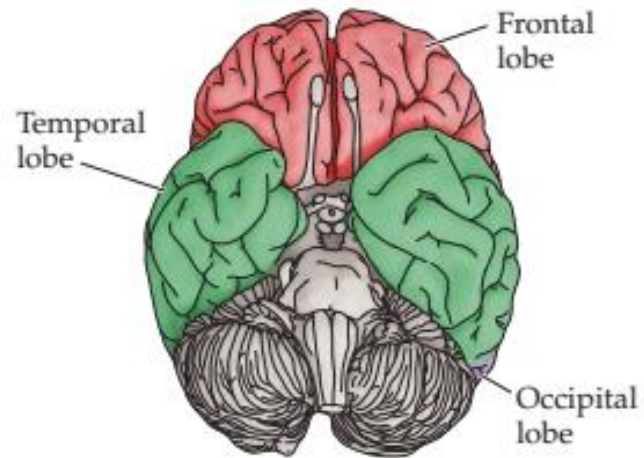
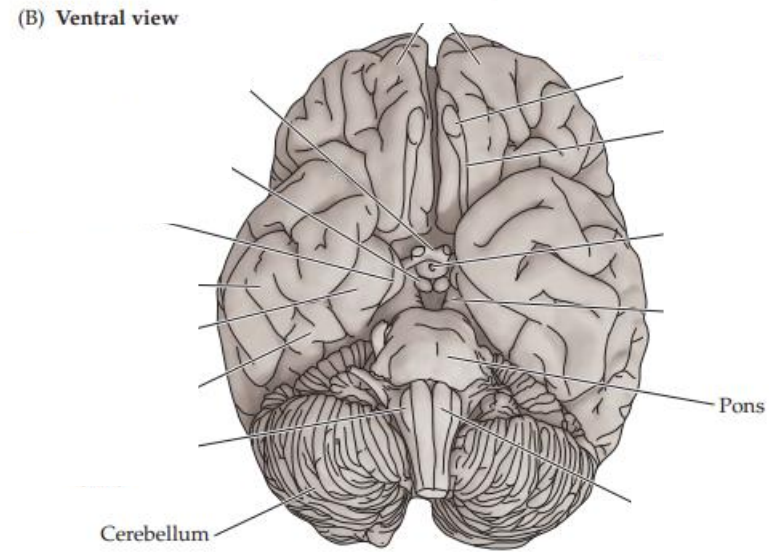
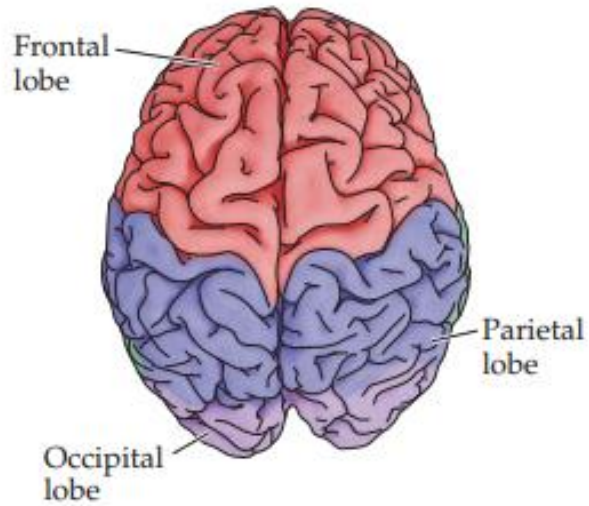
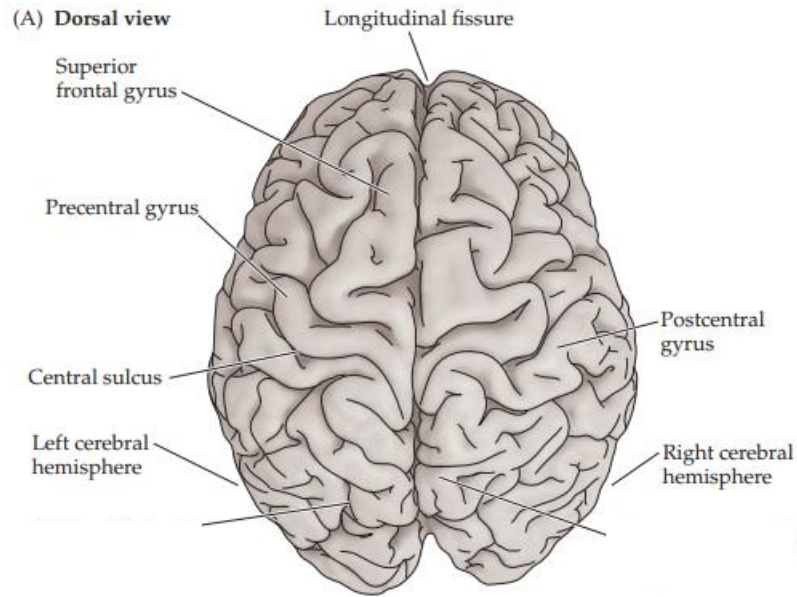


<https://tinyurl.com/bdeuk3r8>



Purves et al., (2018), Appendix

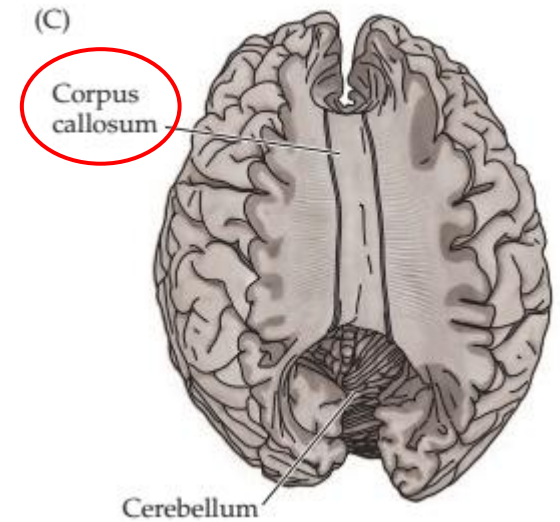
***The central sulcus is also known as the fissure of Rolando, or the Rolandic fissure**



corpus callosum

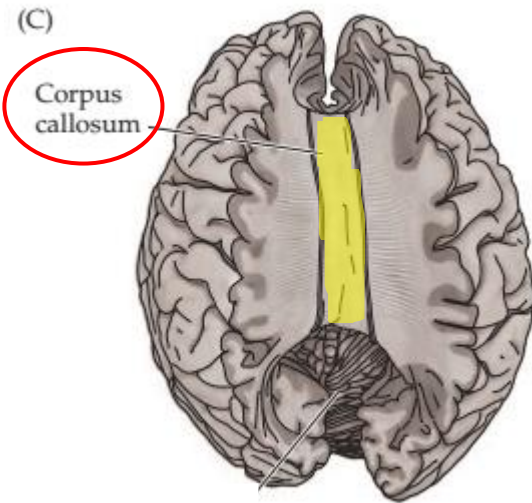
(callosal **commissure**)

a broad band of nerve fibres that **connects** the left and right **hemispheres** of the brain
from Latin: "tough body"

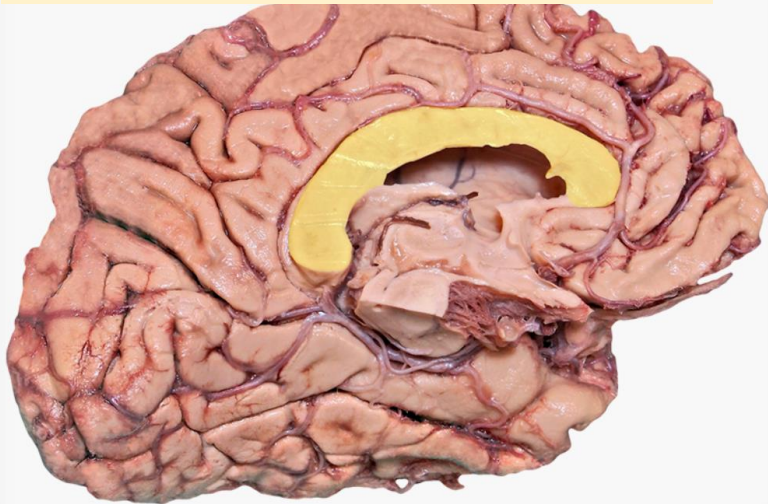

commissure

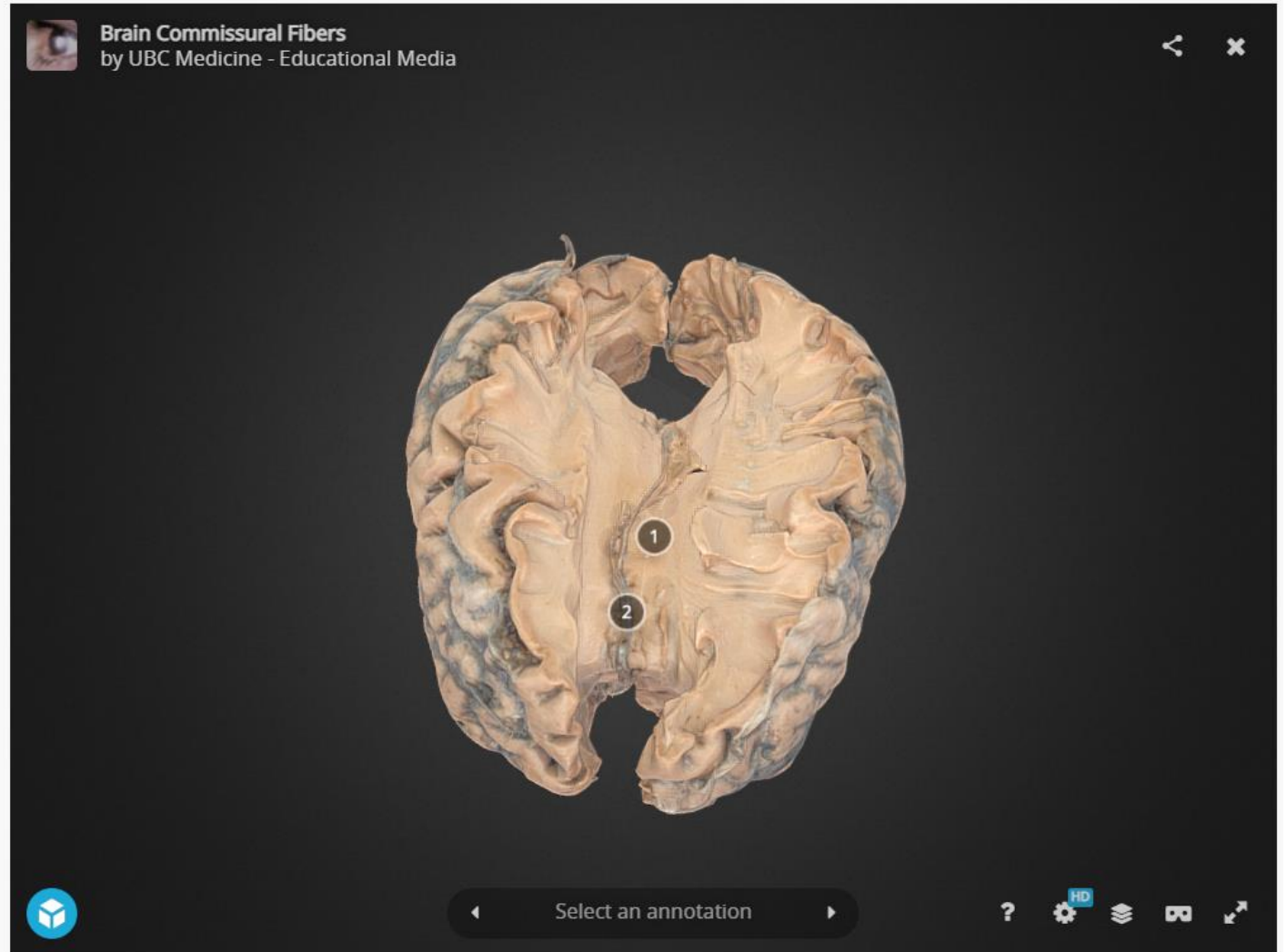
a **connecting** band of nerve tissue in the CNS
from Latin ("commissura"): "joint, juncture"



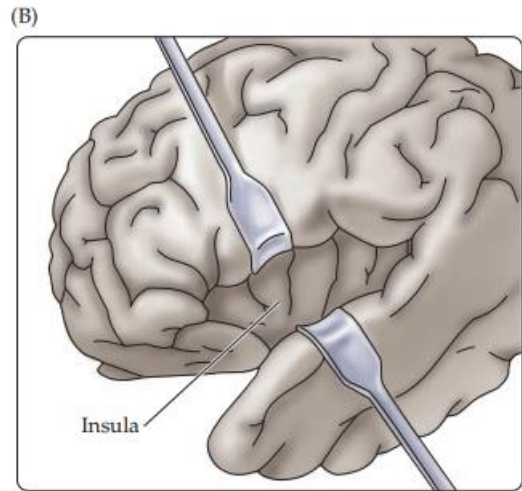
medial view of the corpus callosum (yellow)



<https://neuroanatomy.ca/interactive/CortexMedial.html>

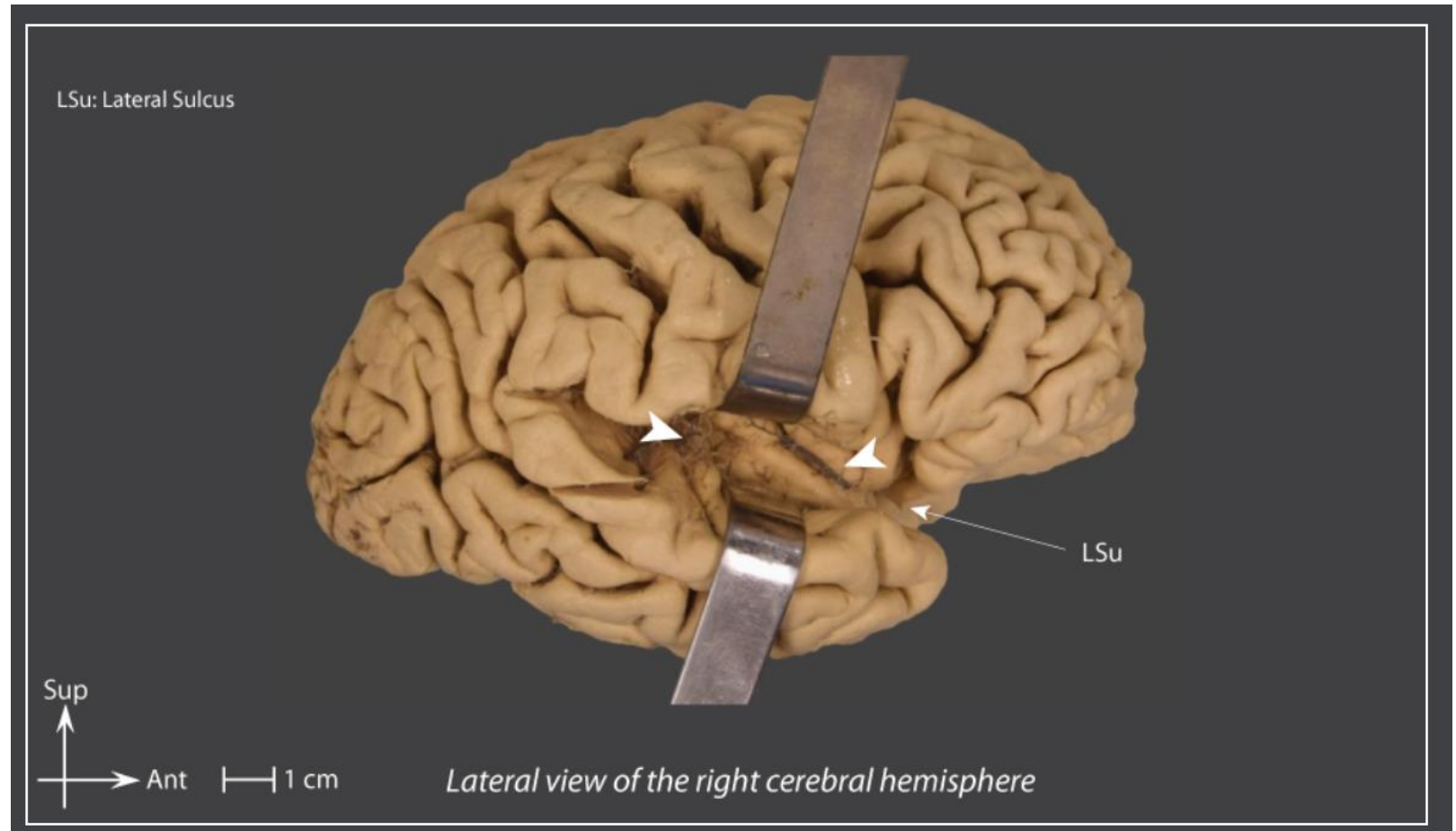


<https://neuroanatomy.ca/3D/3-4brainPG.html>



Purves et al. (2018), Appendix

The banks of the lateral (Sylvian) fissure have been pulled apart to expose the **insula**



<https://sites.uclouvain.be/braininteratlas/en/chapter/external-configuration>

Neuroanatomy Tutorial - Labeled Images

 **Anatomy-Histology main menu**

This tutorial has images in which the structures are labeled. You are to identify the structures by clicking on the name of the structure. The structure whose name is clicked will be identified in the image by an arrow.

External Views

1. **Brain and spinal cord, gross**
2. **Spinal cord nerve roots, gross**
3. **Brain, external view, vertex, gross**
4. **Brain, external view, vertex, Rolandic fissure, gross**
5. **Brain, external view, lateral, gross**
6. **Brain, external view, base of brain, gross**
7. **Brain, cranial nerves, base of brain, gross**
8. **Brain, 12th cranial nerves, base of brain, gross**
9. **Brain, cerebral arteries, base of brain, diagram**
10. **Brain, vertex, arachnoid granulations**

<https://webpath.med.utah.edu/HISTHTML/NEURANAT/NEURANCA.html#1>

■ Six lobes

General view >

• Frontal lobe

- Lateral view of the right cerebral hemisphere >
- Medial view of the left cerebral hemisphere >
- Inferior view of the forebrain >

• Parietal lobe

- Lateral view of the right cerebral hemisphere >
- Medial view of the left cerebral hemisphere >

• Temporal lobe

- Lateral view of the right cerebral hemisphere >
- Medial view of the left cerebral hemisphere >
- Inferior view of the forebrain >

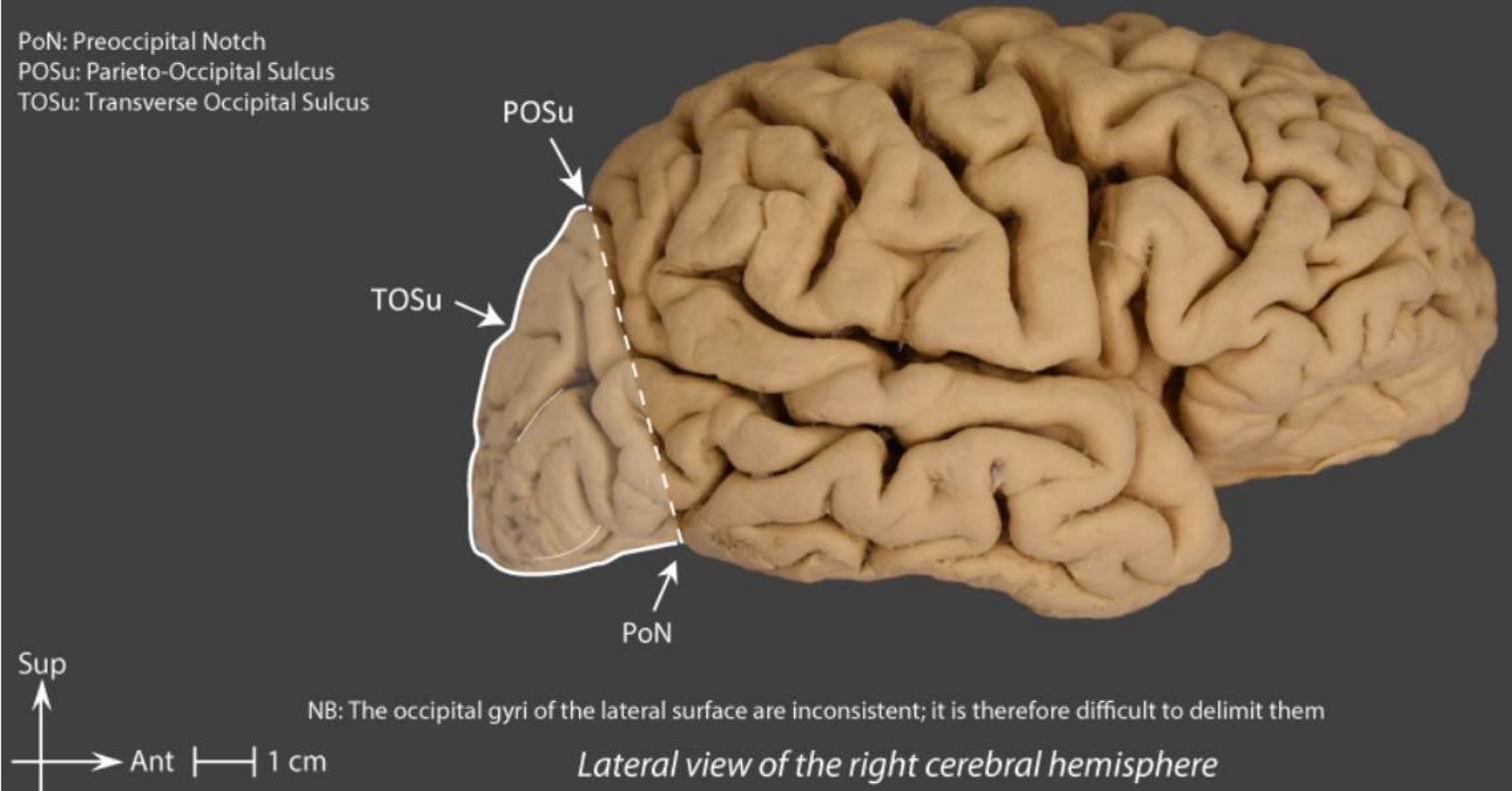
• Occipital lobe

- Lateral view of the cerebral hemisphere >
- Medial view of the cerebral hemisphere >
- Inferior view of the forebrain >

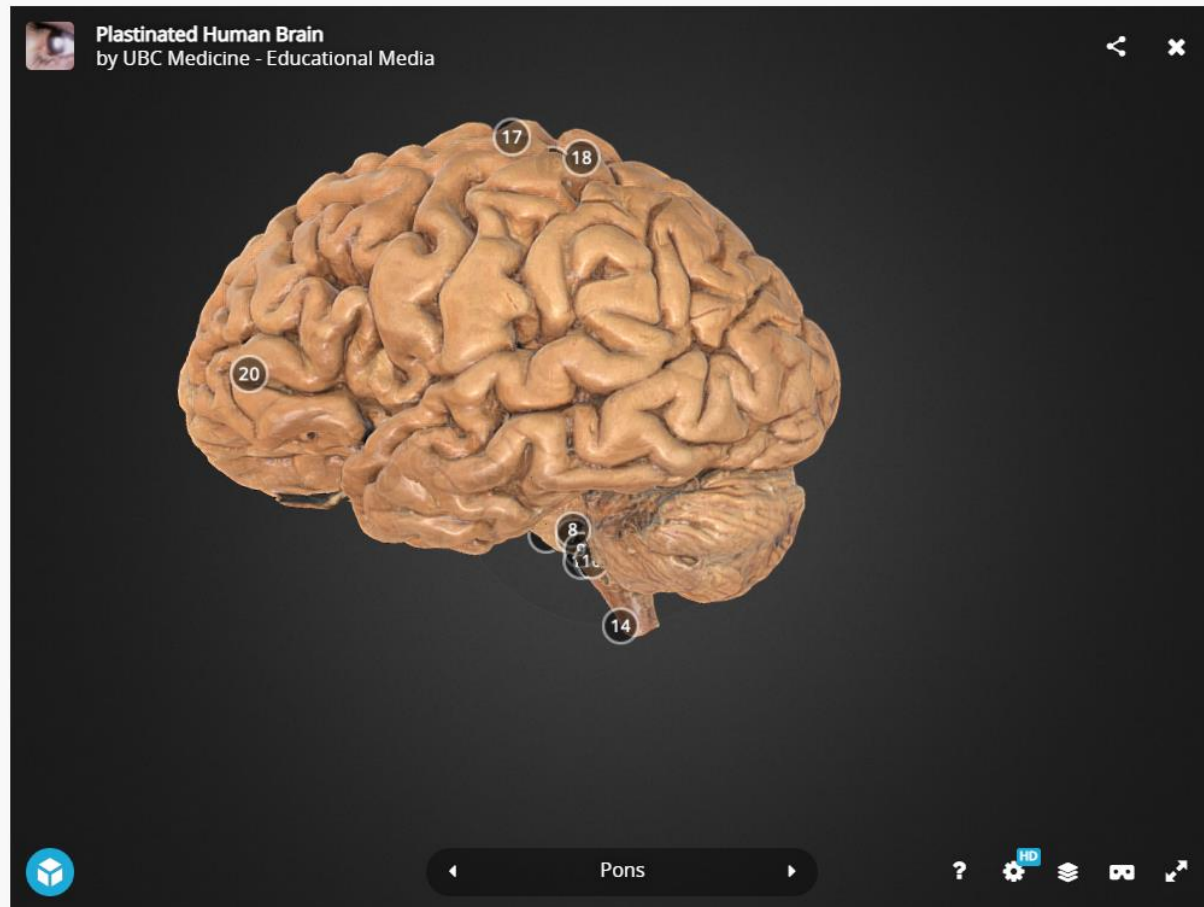
• Insula (insular lobe) >

• Cingulate gyrus >

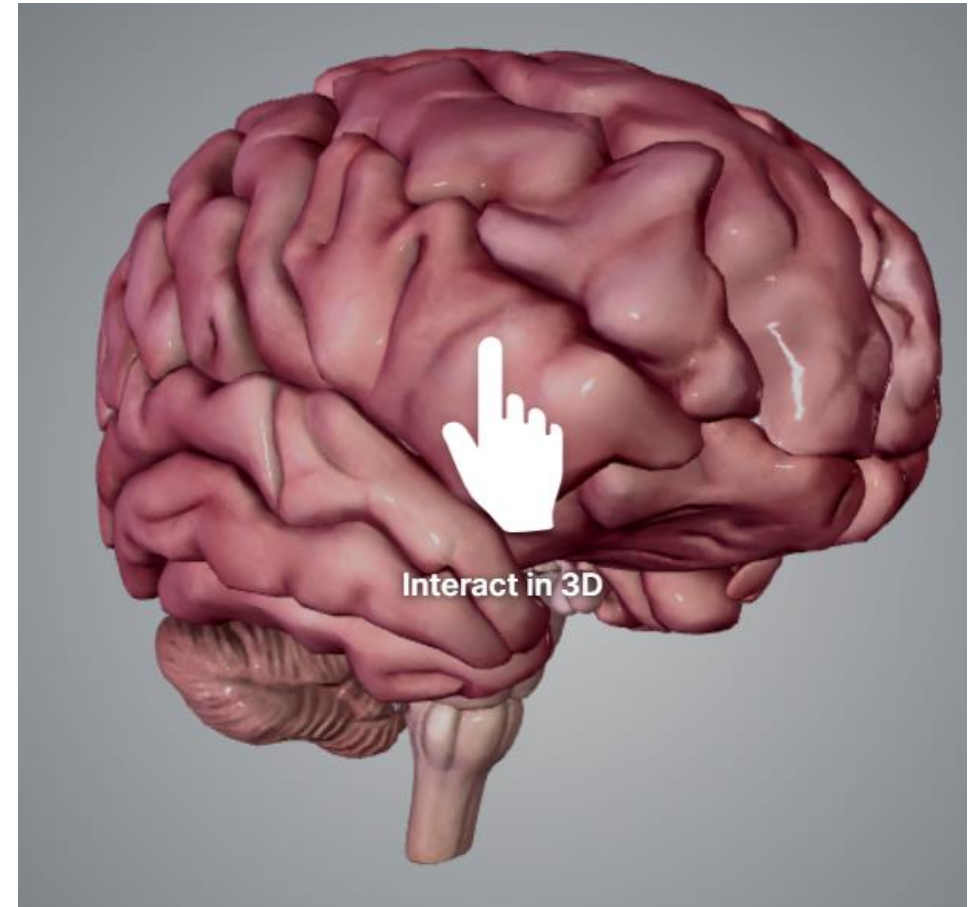
PoN: Preoccipital Notch
 POSu: Parieto-Occipital Sulcus
 TOSu: Transverse Occipital Sulcus



Let's explore all this in 3D



<https://neuroanatomy.ca/3D/wholebrainPG.html>



<https://tinyurl.com/bdeuk3r8>

The meninges

dura mater

tough **outer membrane** surrounding
the brain and the spinal cord
from Latin : "**hard mother**"

arachnoid (mater)

the **middle membrane** surrounding
the brain and spinal cord
from Latin ("arachnoides") and
from Greek ("arakhnoeides"): "**cobweb-like**"

pia mater

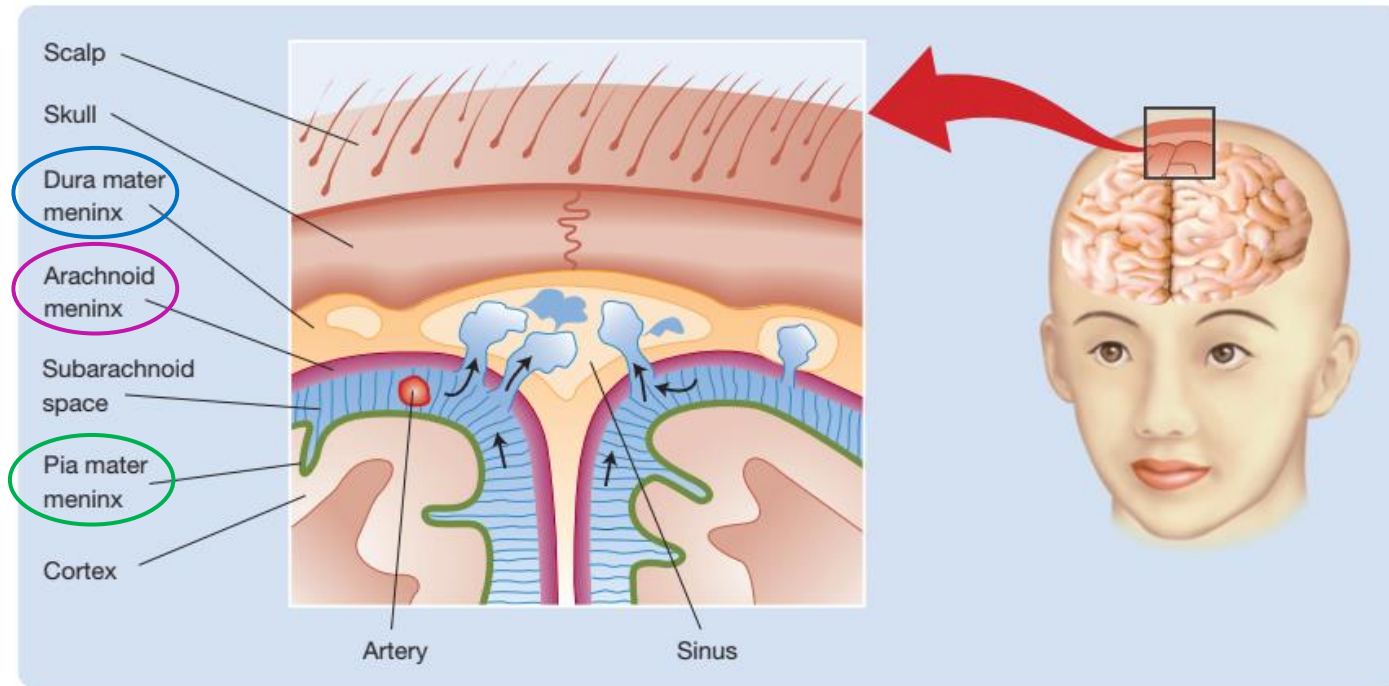
the **innermost layer** of the meninges
from Latin : "**tender mother**"

meninges

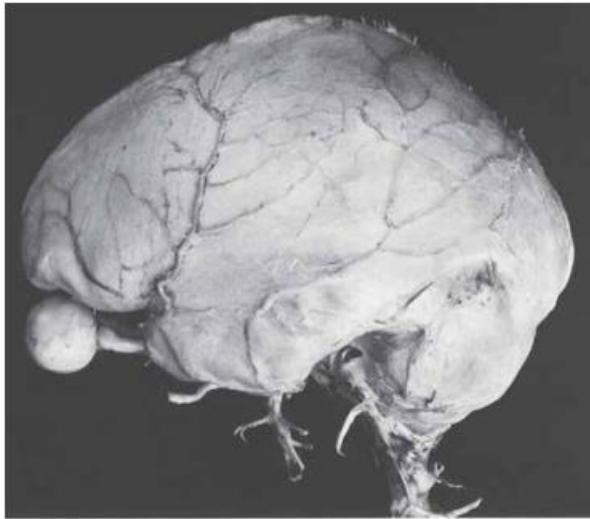
(plural of "meninx")

The three membranes that envelop the brain and spinal cord
from Latin and Greek ("meninx"): "**membrane, covering**"

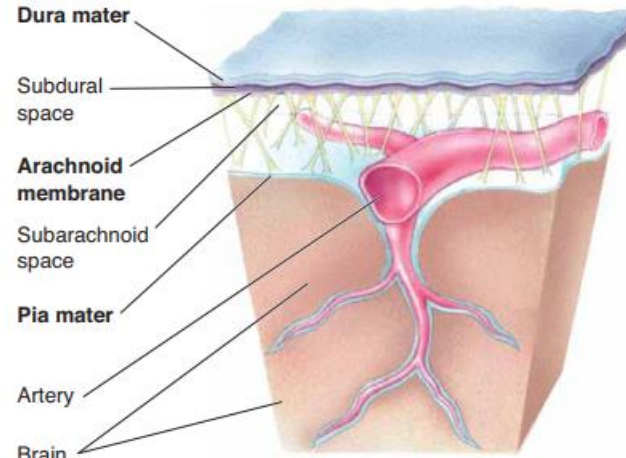
Figure 3.4 The absorption of cerebrospinal fluid (CSF) from the subarachnoid space (blue) into a major sinus. Note the three meninges.



Pinel & Barnes, (2021), p. 76



(a)




(b)

▲ **FIGURE 7.6**

The meninges. (a) The skull has been removed to show the tough outer meningeal membrane, the dura mater. (Source: Gluhbegoric and Williams, 1980.) (b) Illustrated in cross section, the three meningeal layers protecting the brain and spinal cord are the dura mater, the arachnoid membrane, and the pia mater.

Bear et al., (2015), p. 186

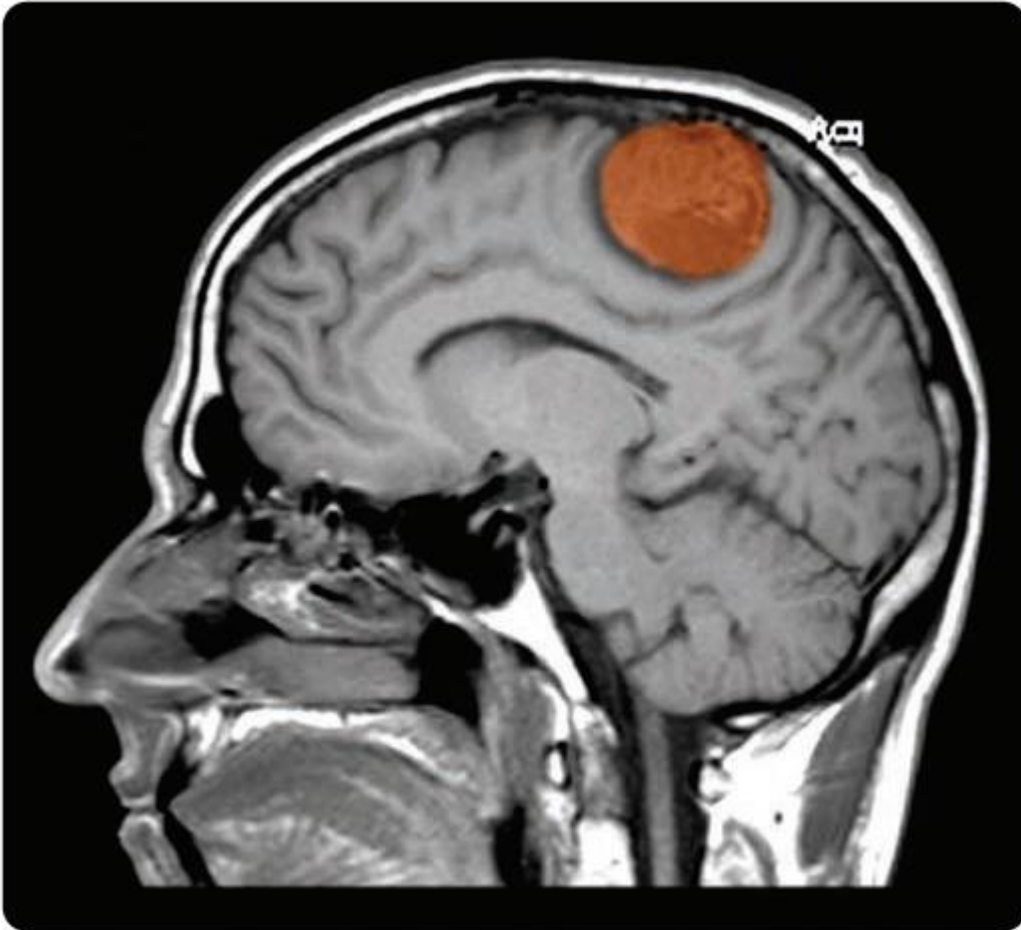The subarachnoid space is filled with a clear liquid called “**cerebrospinal fluid**” (CSF). It also contains **major blood vessels** and **cisterns** (enlarged pockets of CSF created due to the separation of the arachnoid from the pia mater)



See the Munich Brain Course at:
<https://www.intensivkurs-neuroanatomie.de/>

did you know...?

Figure 10.1 A meningioma.



Living Art Enterprises/Science Source

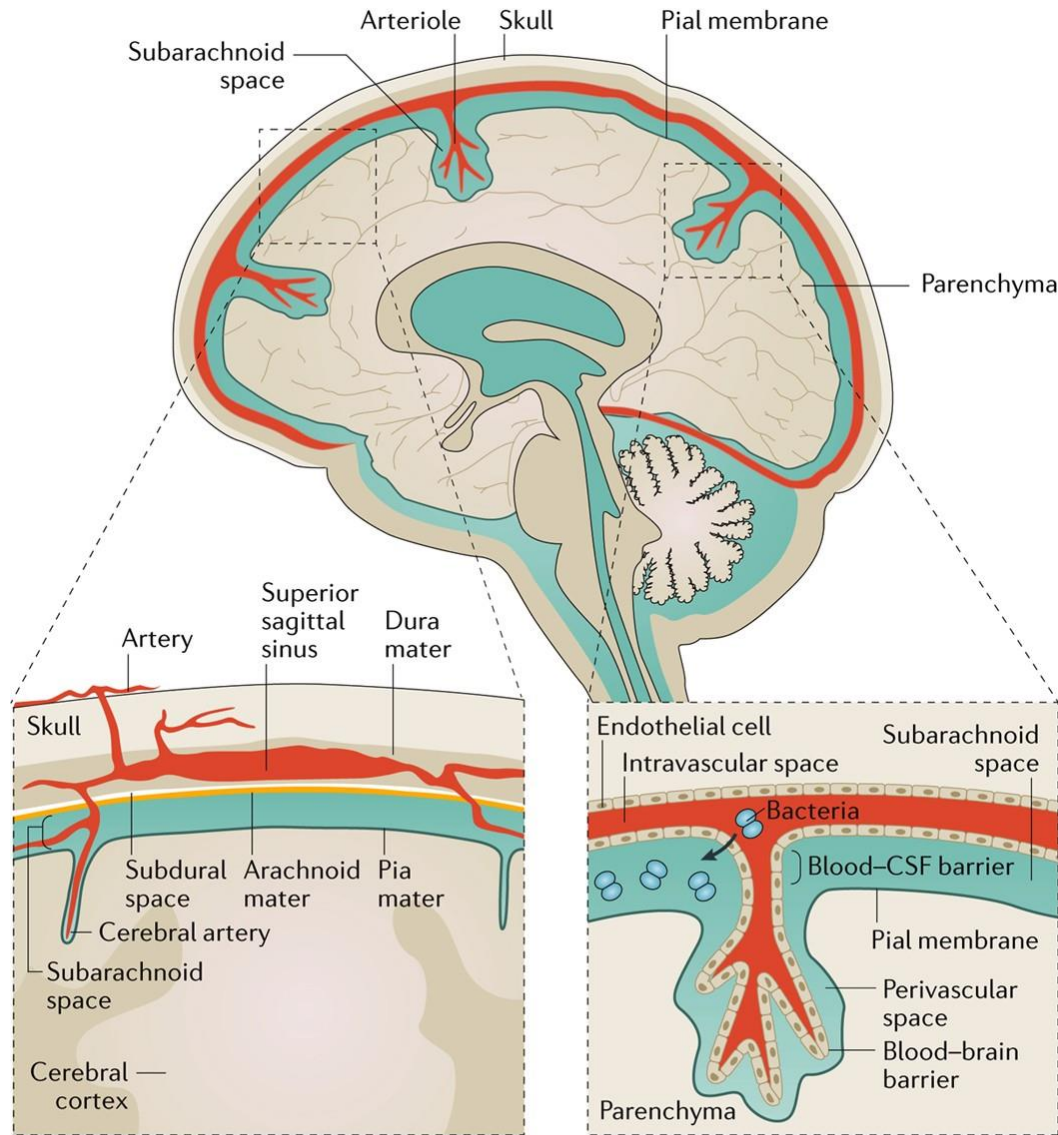
Pinel & Barnes, (2021), p. 260

~ 20% of tumors found in the human brain are **meningiomas** (tumors that grow between the layers of the meninges).

All meningiomas are **encapsulated** tumors (i.e., tumors that grow within their own membrane) => particularly easy to identify on a CT scan.

They can influence the function of the brain only by the **pressure** they exert on surrounding tissue, and they are almost always benign tumors => are surgically removable, with little risk of further growth in the body.

did you know...?



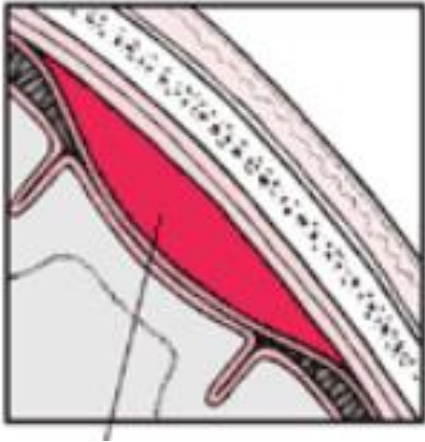
Meningitis is an inflammation of the meninges and subarachnoid space that can also involve the brain **cortex** and **parenchyma** owing to the close anatomical relationship between the cerebrospinal fluid (CSF) and the brain.

Per definition, **bacterial meningitis** is an infection of the CSF-filled subarachnoid space. Inflammation of the meninges and subarachnoid space leads to the classic triad of meningitis symptoms — **headache, fever, and neck stiffness**.

**brain parenchyma refers to the functional tissue in the brain that is made up of the two types of brain cell, neurons and glial cells*

did you know...?

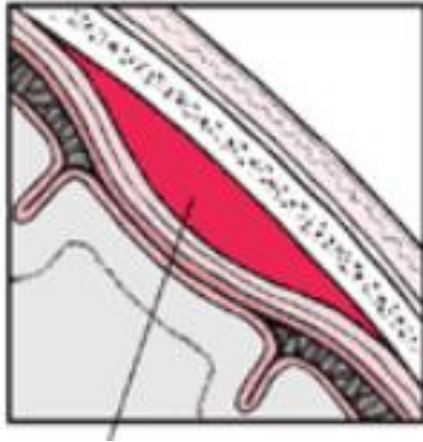
Subdural hemorrhage



Bleeding between
the **arachnoid** mater
and the **dura** mater

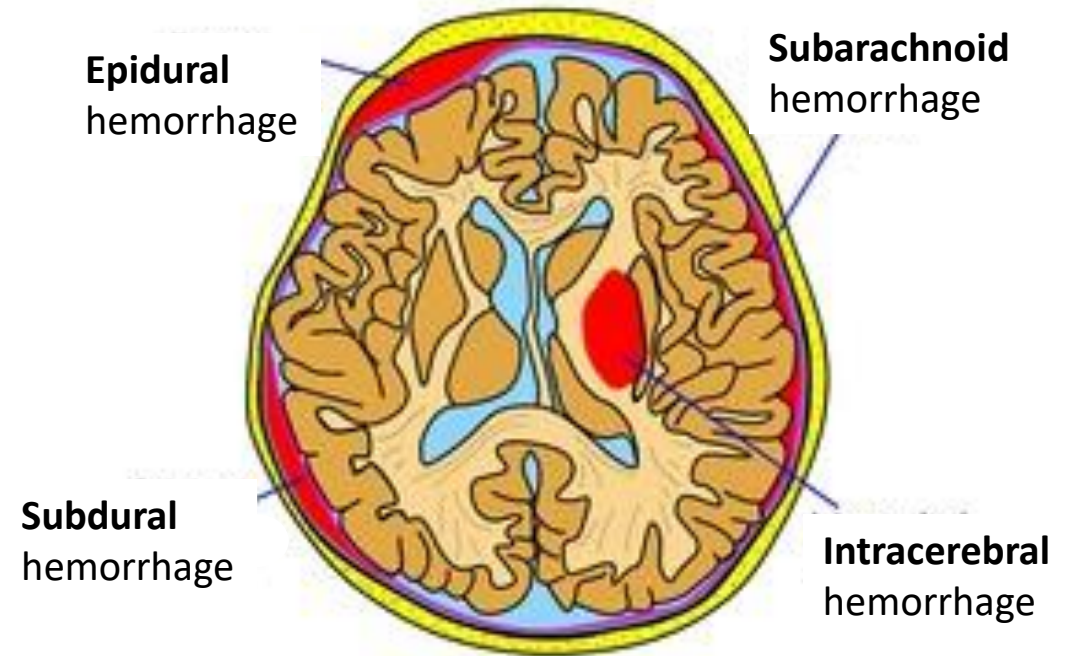
<https://tinyurl.com/585p8xr7>

Epidural hemorrhage



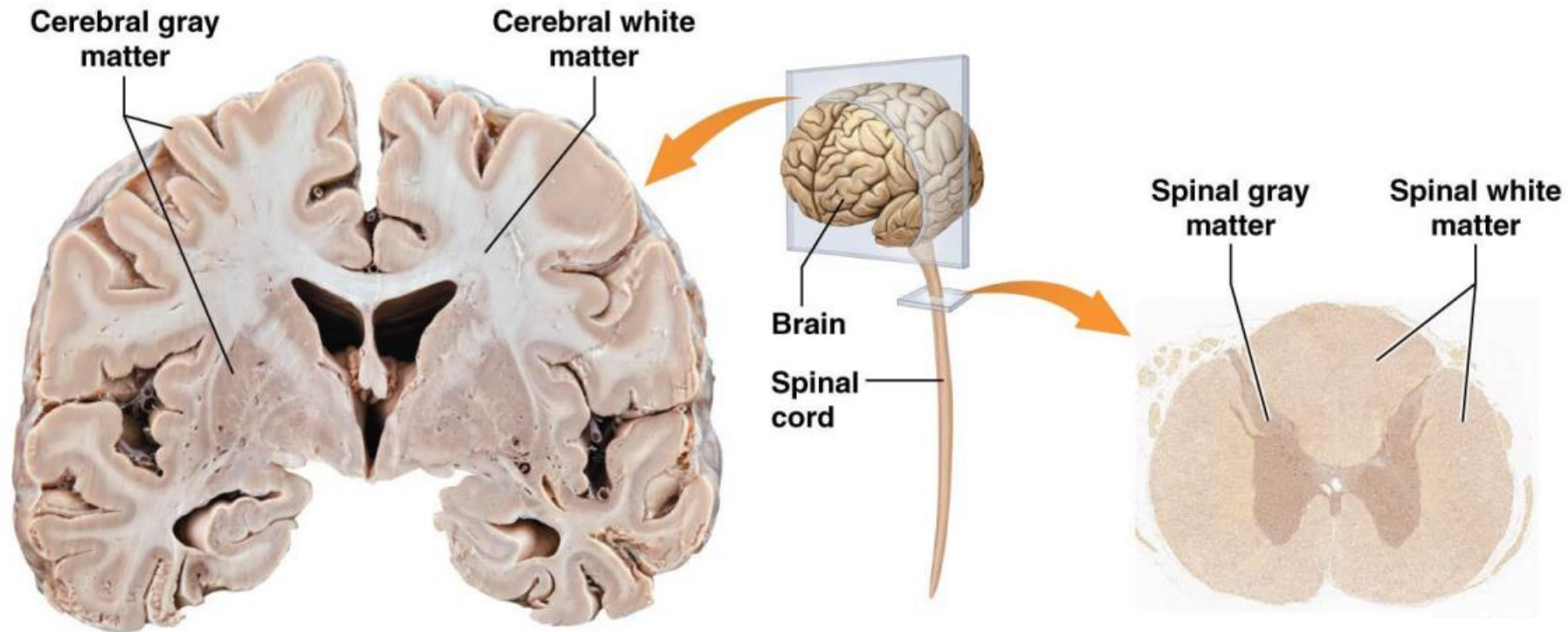
Bleeding between
the **dura** mater and
the **skull**

Intracranial hemorrhage



<https://tinyurl.com/39vwz94k>

A glimpse at subcortical organisation



<https://tinyurl.com/mtki5sap>

gray matter

composed largely of cell bodies
and unmyelinated interneurons

white matter

composed largely of myelinated axons

Let's see all this in 3D



CORTICAL LOCALIZATION

Suzanne Stensaas, PhD

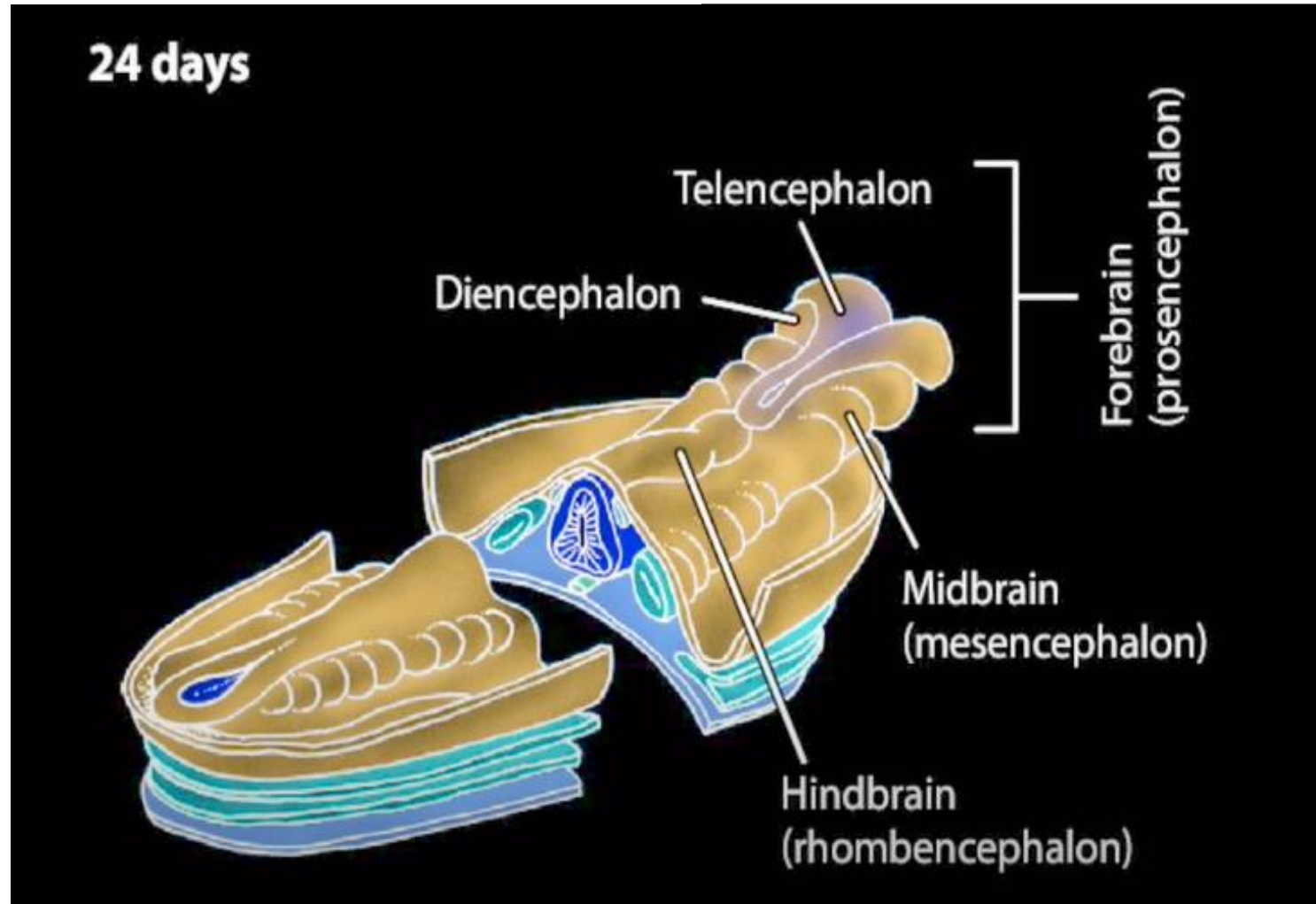
 Department of Neurobiology and Anatomy & Spencer S. Eccles Health Sciences Library
University of Utah, Salt Lake City, Utah, USA

Cortical Localization: Neuroanatomy Video Lab - Brain Dissections

<https://www.youtube.com/watch?v=akjdkBeFNLE>

Embryology

Let's set the stage



<https://www.youtube.com/watch?v=WmqvOUBh2cc>

First week of embryonic development

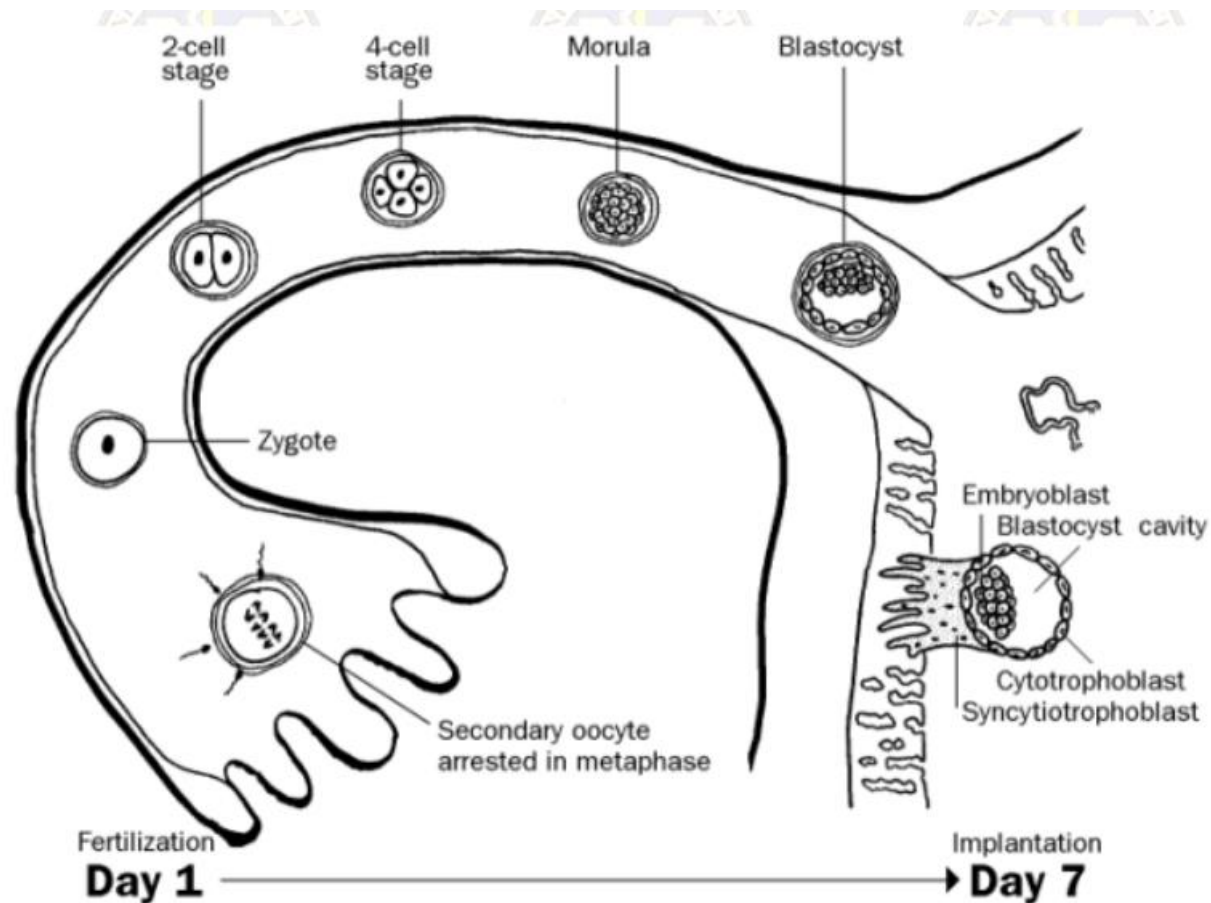


Figure 1 - Summary of the first week of development

<https://www.med.umich.edu/lrc/coursepages/m1/embryology/embryo/03firstweek.htm>

REMEMBER

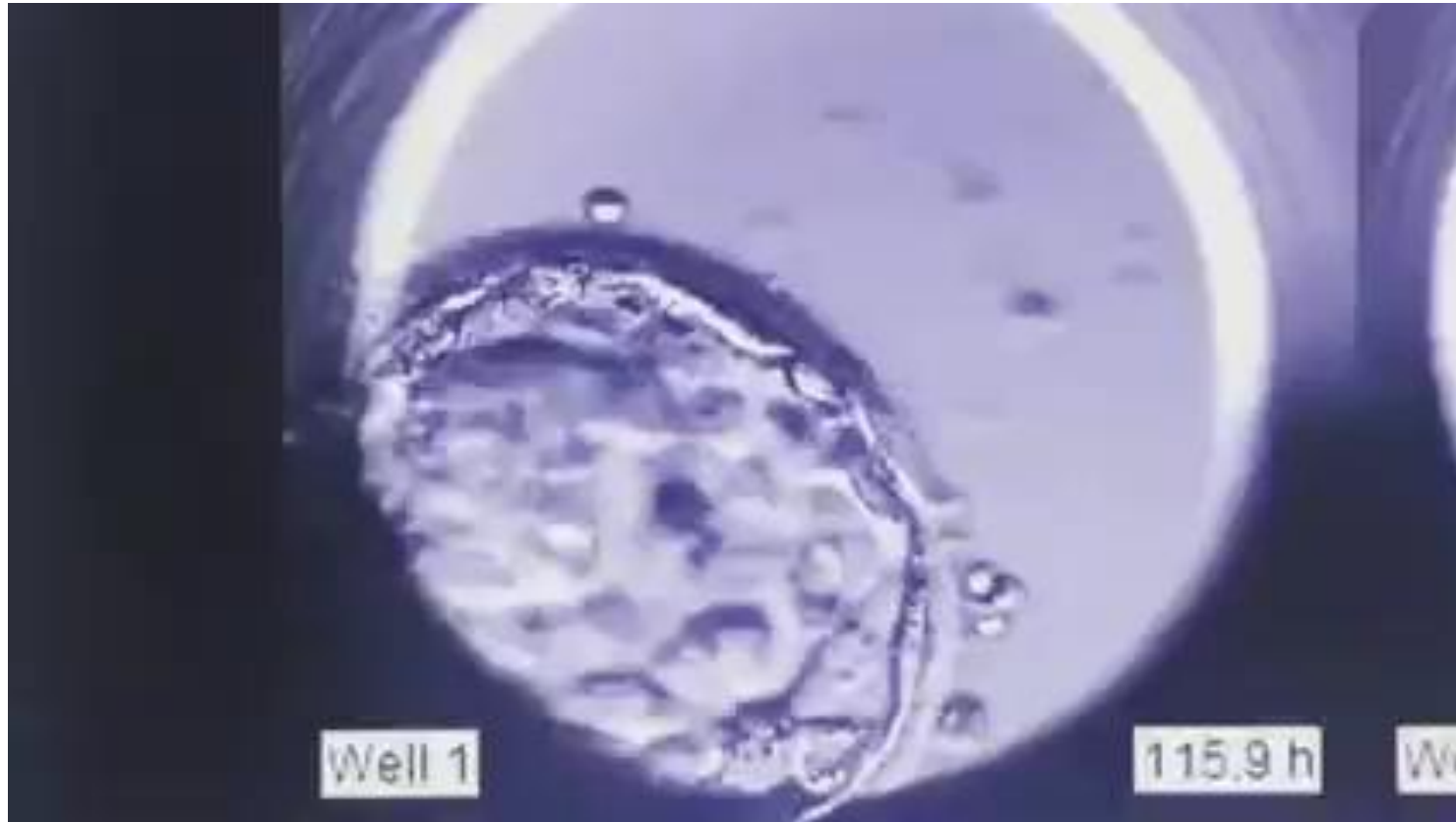
meiosis

a type of cell division for somatic cells and for the **asexual** reproduction of unicellular eukaryotic cells

* mitosis

the type of cell division for the production of **gametes** (reproductive cells) in sexual reproduction

Embryonic cell division



Day 1 - **single cell** with **two nuclei** (**maternal + paternal**) observed.

Day 2 - the **embryo** **divides** into two cells with one nucleus per cell. These cells in turn divide again => an **embryo with four cells**.

Day 3 - The embryo divides again => **eight cells**.

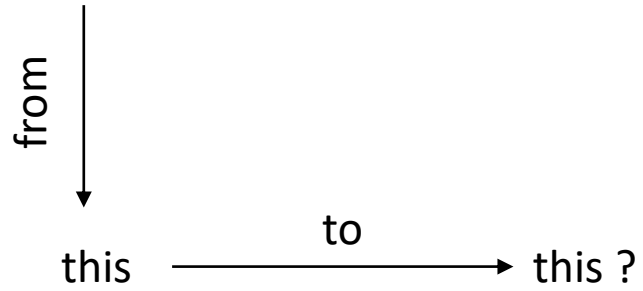
Day 4 - The embryo then divides several times into a default form called a **morula**. Then it begins to compact.

Day 5 - Further division of the embryo continues to form the **blastocyst** which is then released from its surrounding membrane (hatching).

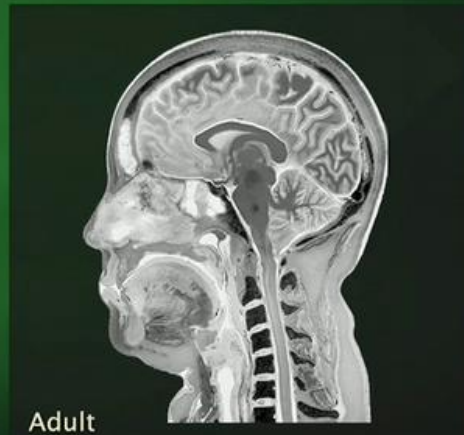
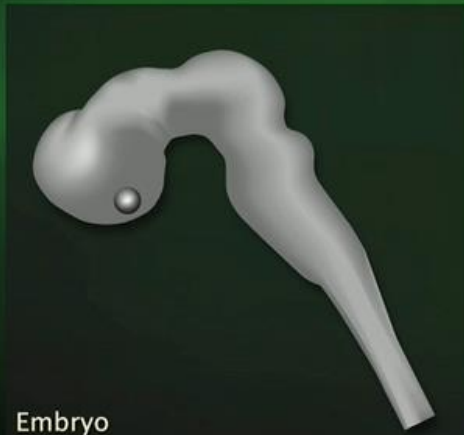<https://tinyurl.com/tmrpj2dv>

Embryonic nervous system starts taking shape

How do we go



Origins of brain pattern

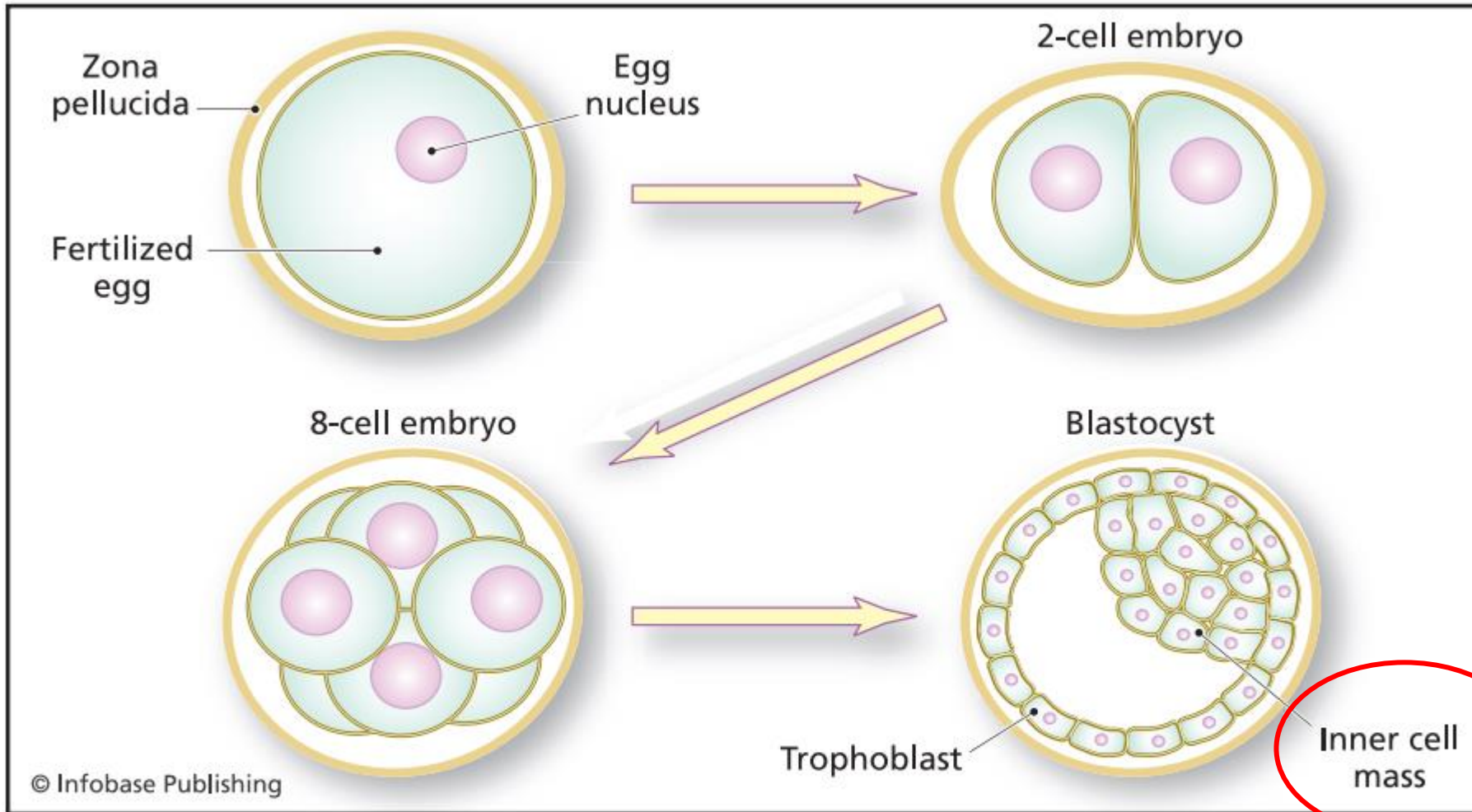


Making Your Mind: Molecules, Motion, and Memory
Lecture 2 – Building Brains: The Molecular Logic of Neural Circuits
by Thomas M. Jessell, PhD

1
Month

-43:30

<https://media.hhmi.org/hl/08Lect2.html>



* trophoblast => supplies nourishment to the embryo => placenta

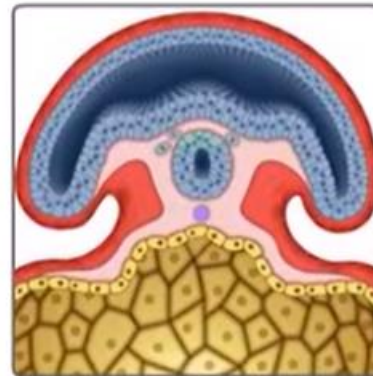
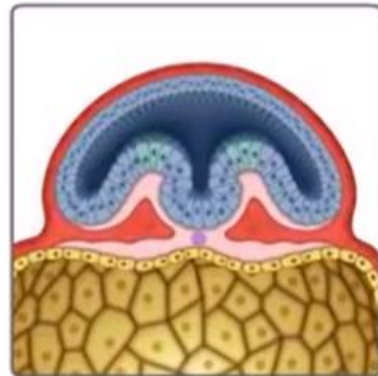
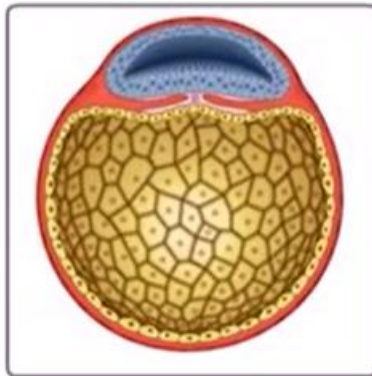
* zona pellucida = thick transparent membrane surrounding a mammalian ovum before implantation

Figure 2.1 A fertilized egg (zygote) undergoes multiple cell divisions to become a blastocyst. The inner cell mass of the blastocyst then forms three distinct layers—ectoderm, mesoderm, and endoderm—that will give rise to all the different tissues of the human body.

Neurulation

In summary, neurulation occurs during the third week of embryonic development.

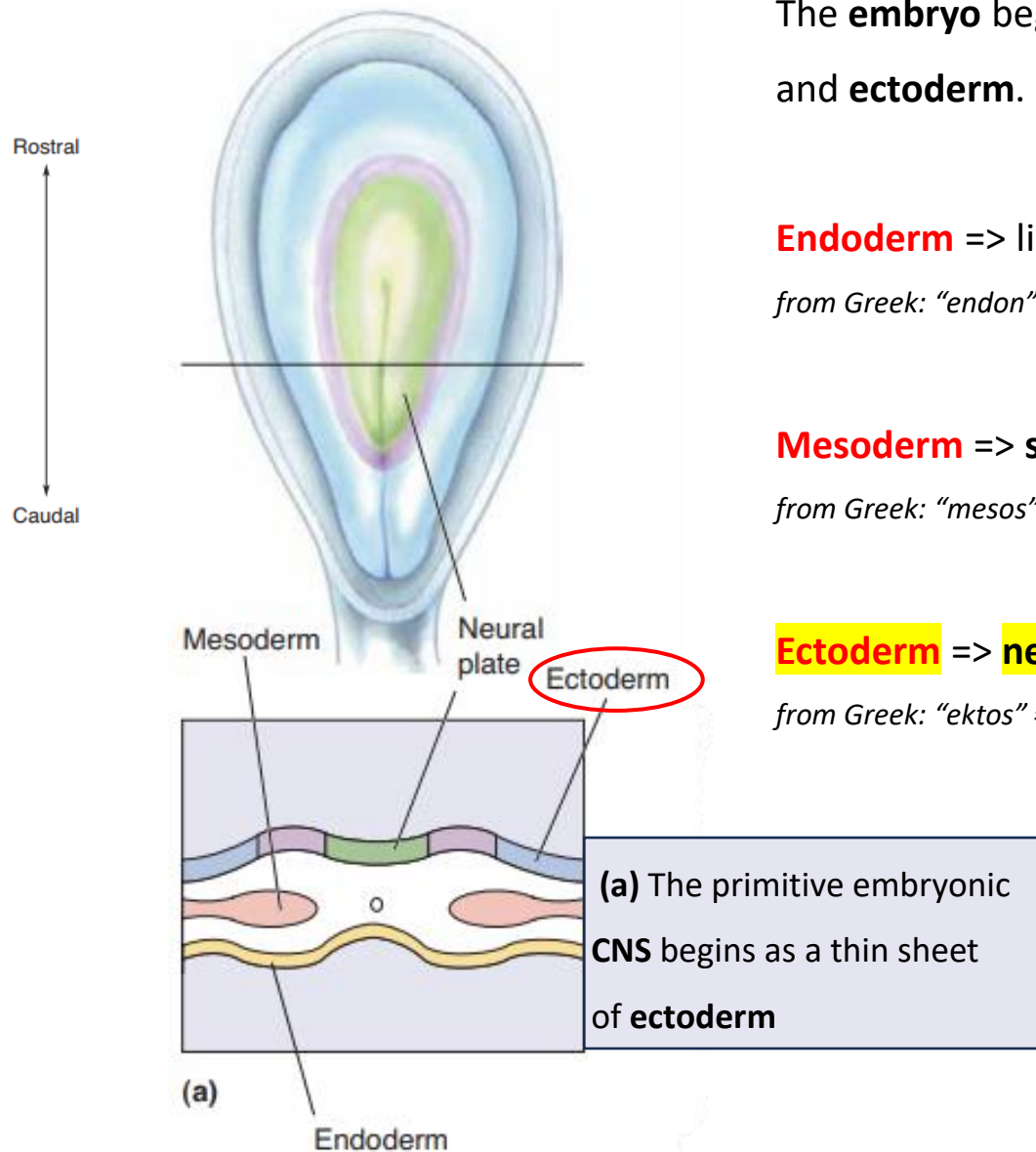
The transformation of the neural plate into a neural tube marks the beginning of the formation of the central nervous system.



- A neural plate of thickened cells forms in a cranial to caudal direction.
- The lateral edges of the neural plate elevate and fuse to form the neural tube.
- Neural crest cells contribute to the formation of the peripheral nervous system.

<https://www.youtube.com/watch?v=IGLexQR9xGs>

~ 17 days post-conception



The **embryo** begins as a **flat disk** with three distinct **layers** of cells: **endoderm**, **mesoderm**, and **ectoderm**.

Endoderm => lining of internal organs => gastrointestinal and respiratory **organs**

from Greek: "endon" = "within"; "derma" = "skin"

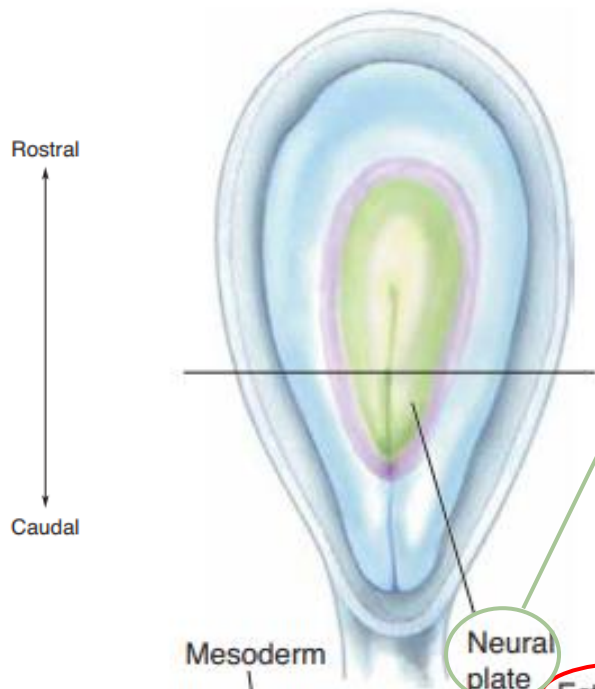
Mesoderm => **skeleton** and **muscles**

from Greek: "mesos" = "middle"; "derma" = "skin"

Ectoderm => **nervous system** and skin

from Greek: "ektos" = "outside"; "derma" = "skin"

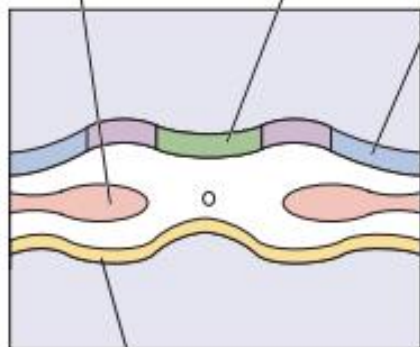
The process by which embryonic cells of the **ectoderm** receive signals to form the neural plate (**cell fate specification**), and hence lead to the formation of neural structures, is called **neural induction**.



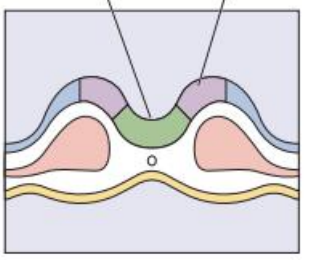
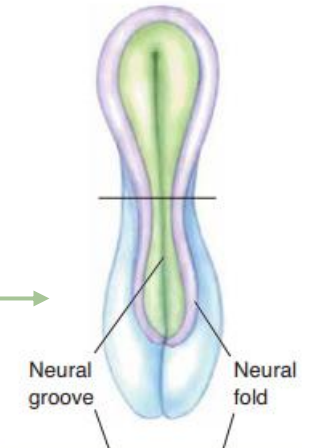
It is the **neural plate** part of the ectoderm that gives rise to the **CNS**

The ectoderm starts folding, forming the **neural groove**. The walls of the neural groove are called **neural folds**.

Mesoderm
Neural plate
Ectoderm



(a) The primitive embryonic **CNS** begins as a thin sheet of **ectoderm**

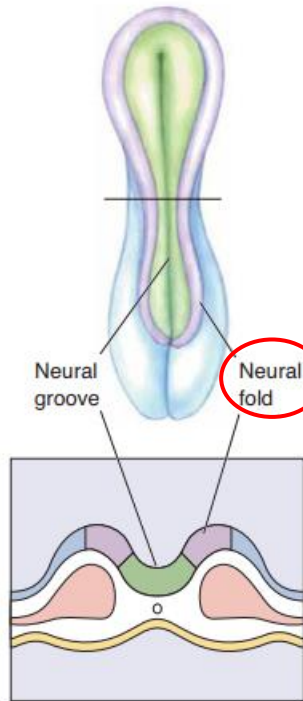


(b) The first important step in the development of the CNS is the formation of the **neural groove**

(a)
Endoderm

~ 22 days post-conception

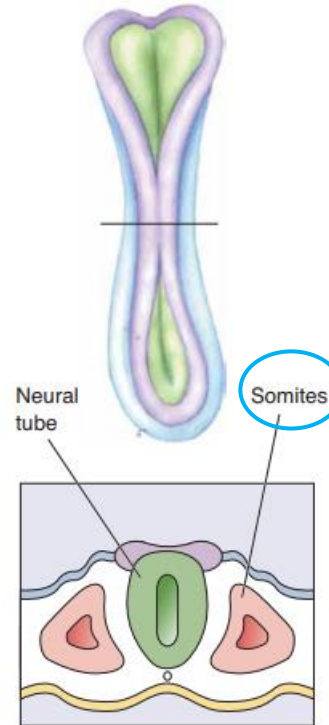
Rostral
↑
↓
Caudal



The **neural folds** come together and fuse, forming the **neural tube**

(b)

(b) The first important step in the development of the CNS is the formation of the **neural groove**



(c)

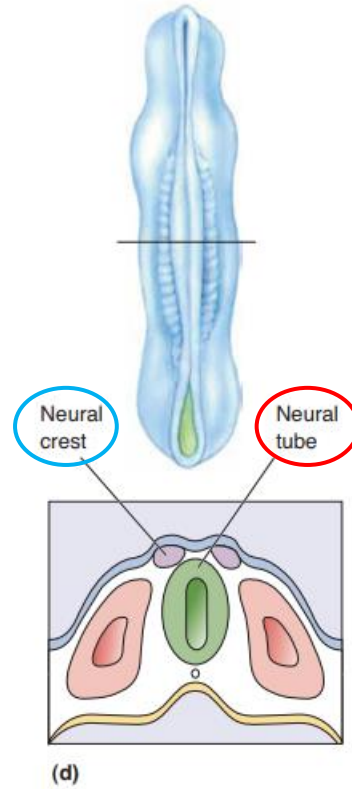
(c) The **neural folds** fuse, forming the **neural tube**

The **somites** are portions of **mesoderm** that give rise to the 33 **vertebrae** of the vertebral column (spine), **rib cage**, part of the **occipital bone**, **skeletal muscle**, **cartilage**, **tendons**, and **skin** (of the back)

Neurulation is now complete

Rostral
↑
↓
Caudal

The **PNS** develops from the neural crest



The **CNS** develops from the walls of the neural tube

(d) The bits of neural ectoderm that are pinched off when the tube rolls up is called the **neural crest**

Bear et al., (2015), p. 193

Stages of neurulation

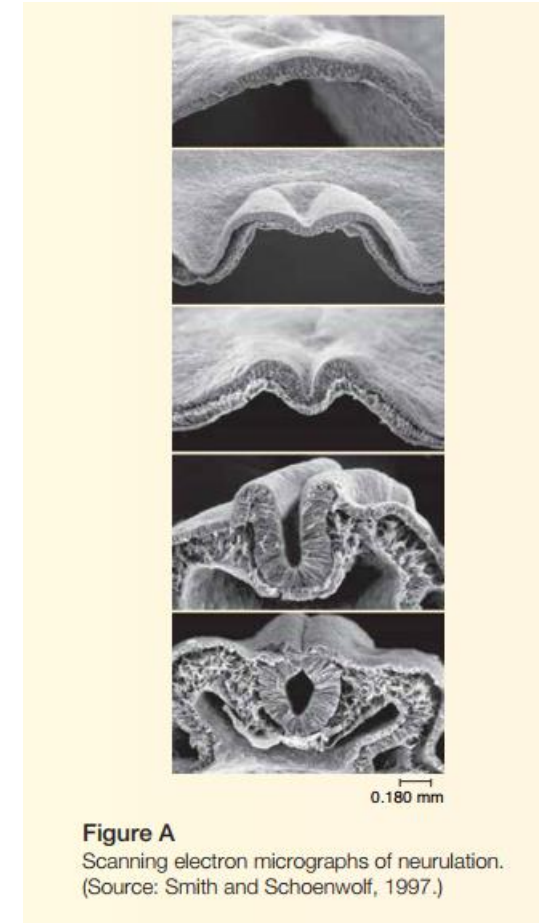
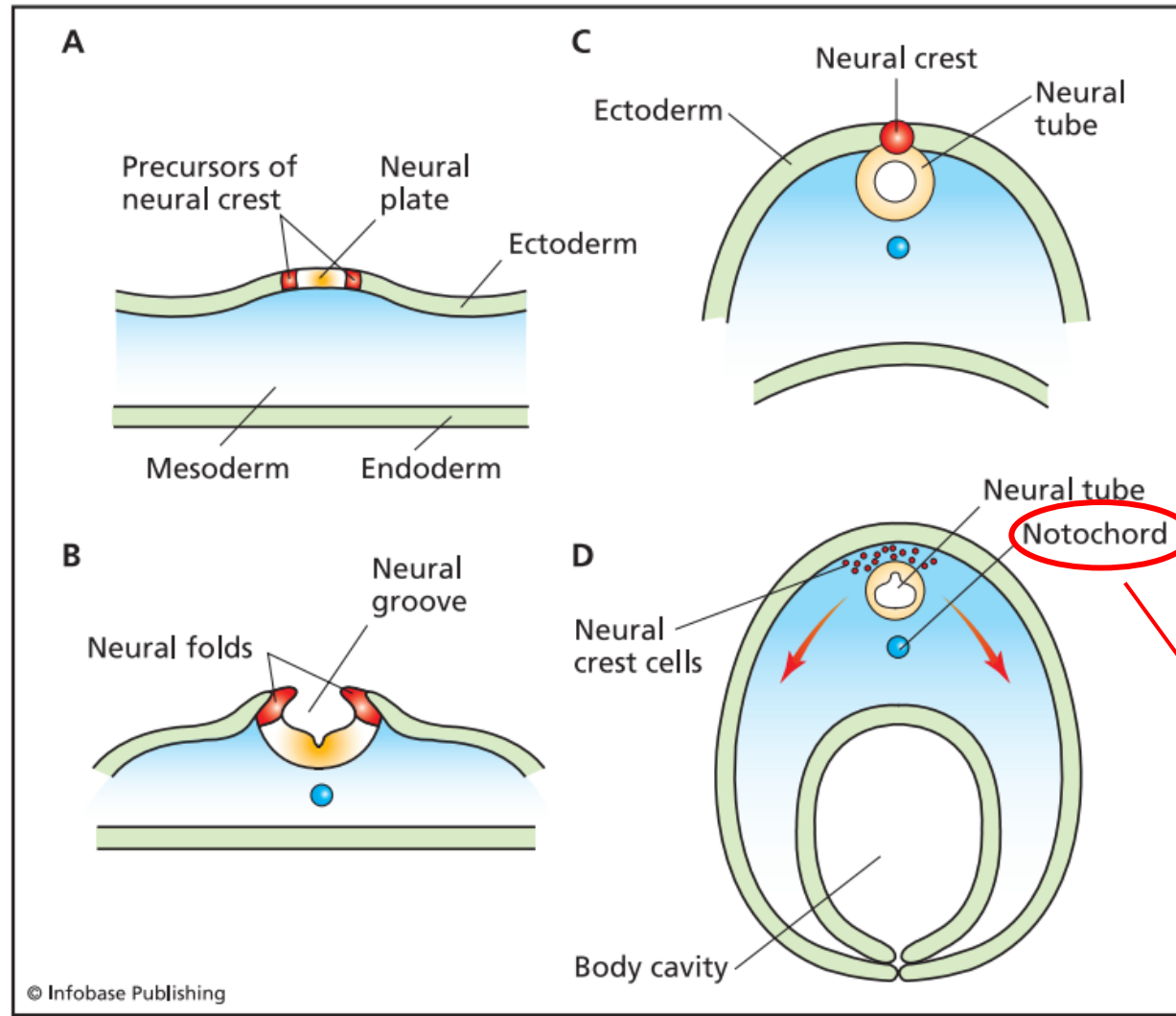


Figure A
Scanning electron micrographs of neurulation.
(Source: Smith and Schoenwolf, 1997.)

Bear et al., (2015), p. 194

Neurulation at a glance



The development of the nervous system begins with the formation of the **neural plate** (A).

The neural plate then folds inward to form the **neural tube** and the **neural crest** (B).

The **neural tube** eventually gives rise to the **CNS** (brain and spinal cord), while the **neural crest** cells diffuse to other parts of the developing embryo and give rise to the **PNS** (peripheral nervous system).

secretes the **signaling protein** which instructs the surrounding cells to **specialize**, e.g., the differentiation of the dorsal and ventral sides of the neural tube

Neurogenesis and neural migration

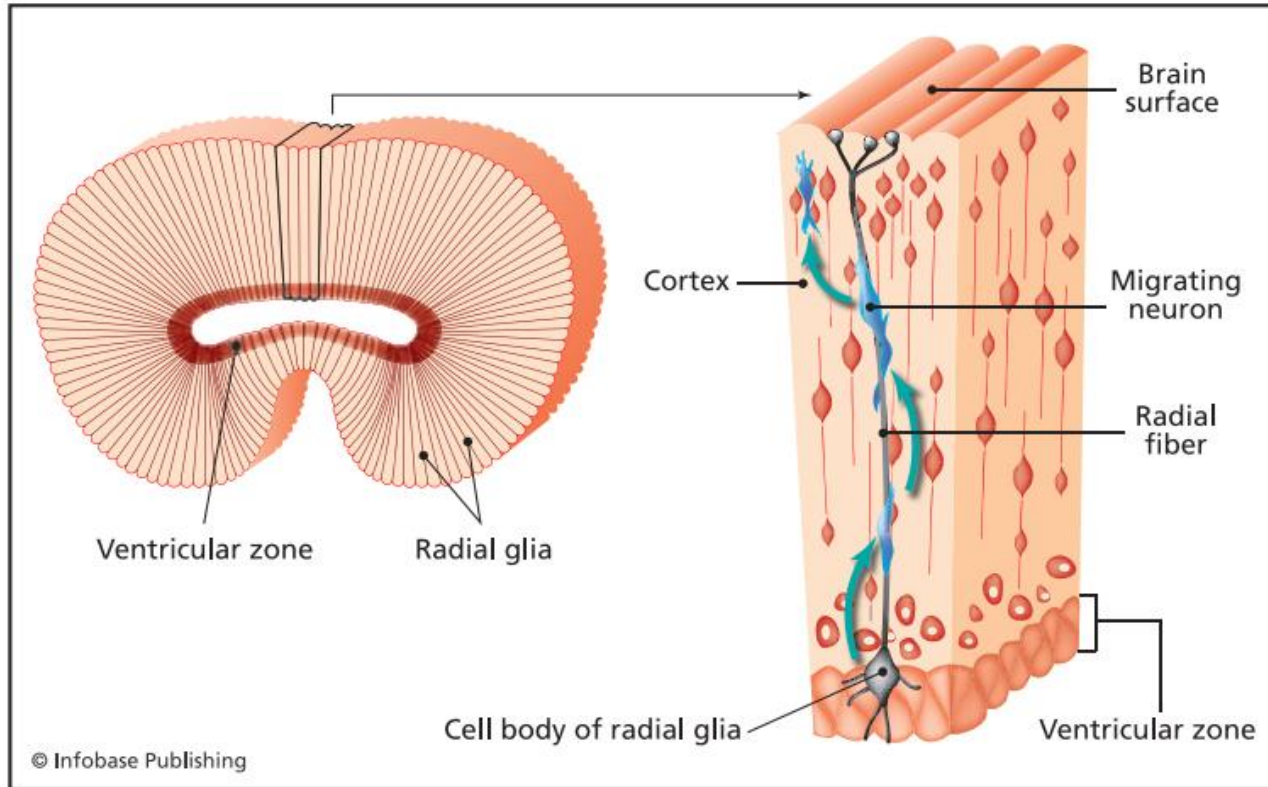


Figure 3.2 Radial glia act as guides for newly formed neurons by leading them to their final destinations in the cerebral cortex.

Bangalore, (2007), p. 28

Those neurons in the emerging brain and spinal cord that are the last to be generated migrate to the most superficial layers of the gray matter, whereas neurons generated earlier in development remain in the deepest layers of the brain.

The cells of the neural tube are undifferentiated stem cells known as **neural precursor cells**.

Neurons and glial cells are generated from these neural precursor cells, most between weeks 6 and 8 of gestation and nearly all before the end of the second trimester.

Thus, virtually all the neurons in the neocortex on which cognition will mainly depend are present in the late-stage human embryo.

The locus of cell division is at the inner surface of the neural tube, a region called the **ventricular zone**. The neuronal precursor cells migrate outward (toward the surface of the neural tube), where they eventually **differentiate** into neurons.

Watch a neuron migrating along the radial fiber of a radial glia



<https://www.youtube.com/watch?v=ZRF-gKZHINK>

Conceptual clarifications

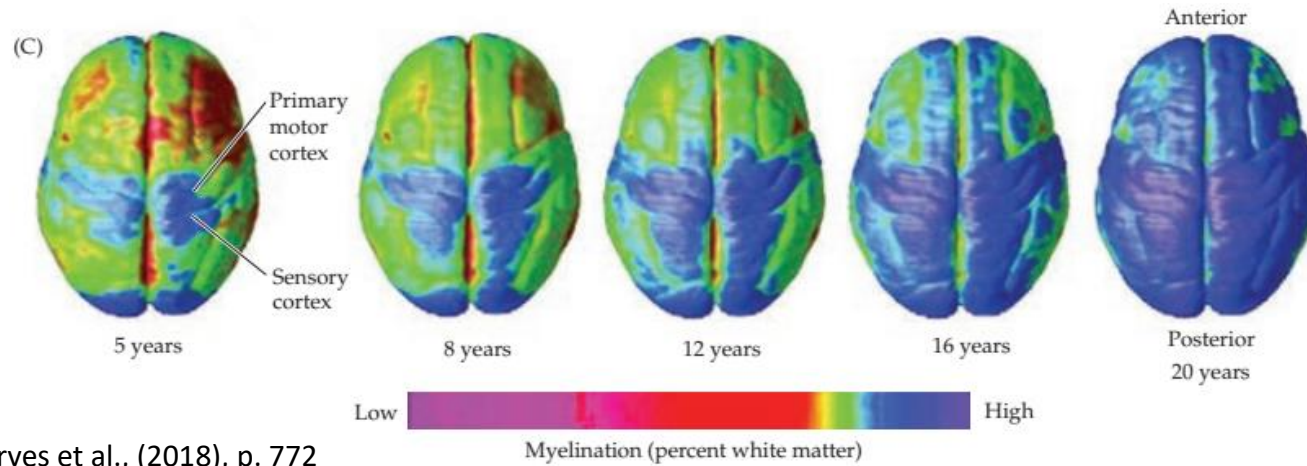
Identification of Neural Stem Cells

Neurobiologists routinely use various terms interchangeably to describe undifferentiated cells of the CNS. The most commonly used terms are “stem cell”, “precursor cell” and “progenitor cell”. The inappropriate use of these terms to identify undifferentiated cells in the CNS has led to confusion and misunderstandings in the field of NSC and neural progenitor cell research. However, these different types of undifferentiated cells in the CNS technically possess different characteristics and fates. For clarity, the terminology used here is:

- **Neural Stem Cell (NSCs):** Multipotent cells which are able to self-renew and proliferate without limit, to produce progeny cells which terminally differentiate into neurons, astrocytes and oligodendrocytes. The non-stem cell progeny of NSCs are referred to as neural progenitor cells.
- **Neural Progenitor Cell:** Neural progenitor cells have the capacity to proliferate and differentiate into more than one cell type. Neural progenitor cells can therefore be unipotent, bipotent or multipotent. A distinguishing feature of a neural progenitor cell is that, unlike a stem cell, it has a limited proliferative ability and does not exhibit self-renewal.
- **Neural Precursor Cells (NPCs):** As used here, this refers to a mixed population of cells consisting of all undifferentiated progeny of neural stem cells, therefore including both neural progenitor cells and neural stem cells. **The term neural precursor cells is commonly used to collectively describe the mixed population of NSCs and neural progenitor cells derived from embryonic stem cells and induced pluripotent stem cells.**

<https://tinyurl.com/435jt6s8>

Myelination, synaptogenesis and synaptic pruning



Purves et al., (2018), p. 772

Begins relatively late in human gestation (at about **29 weeks**), and many major white matter tracts are not fully myelinated until **adolescence**.

Time course of myelination

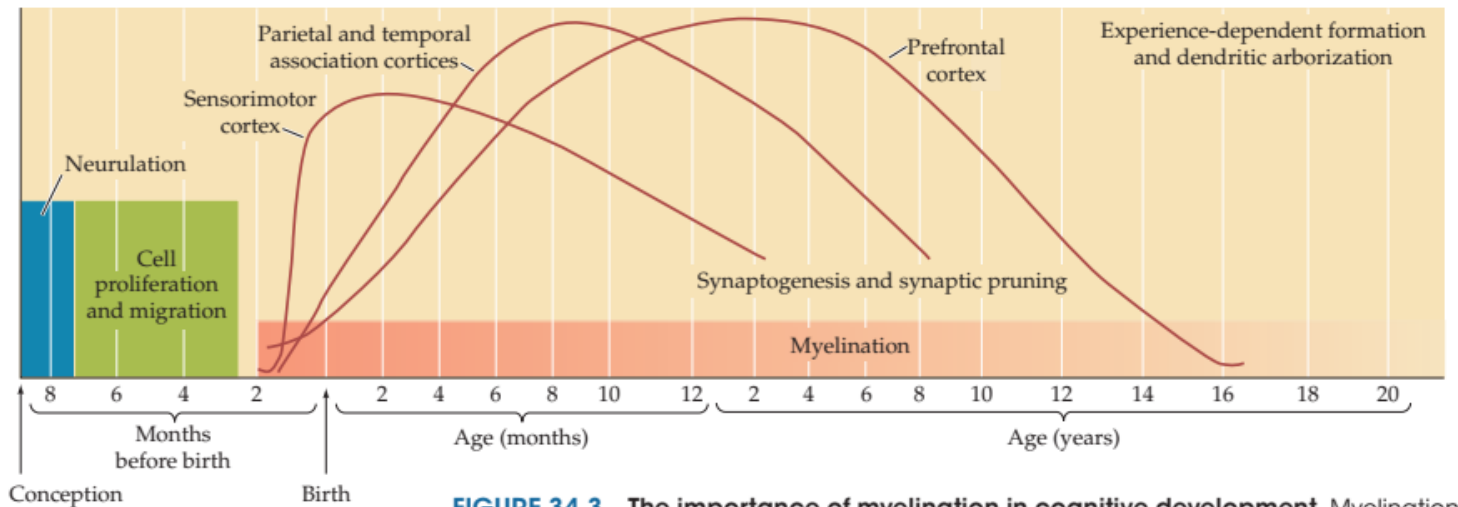
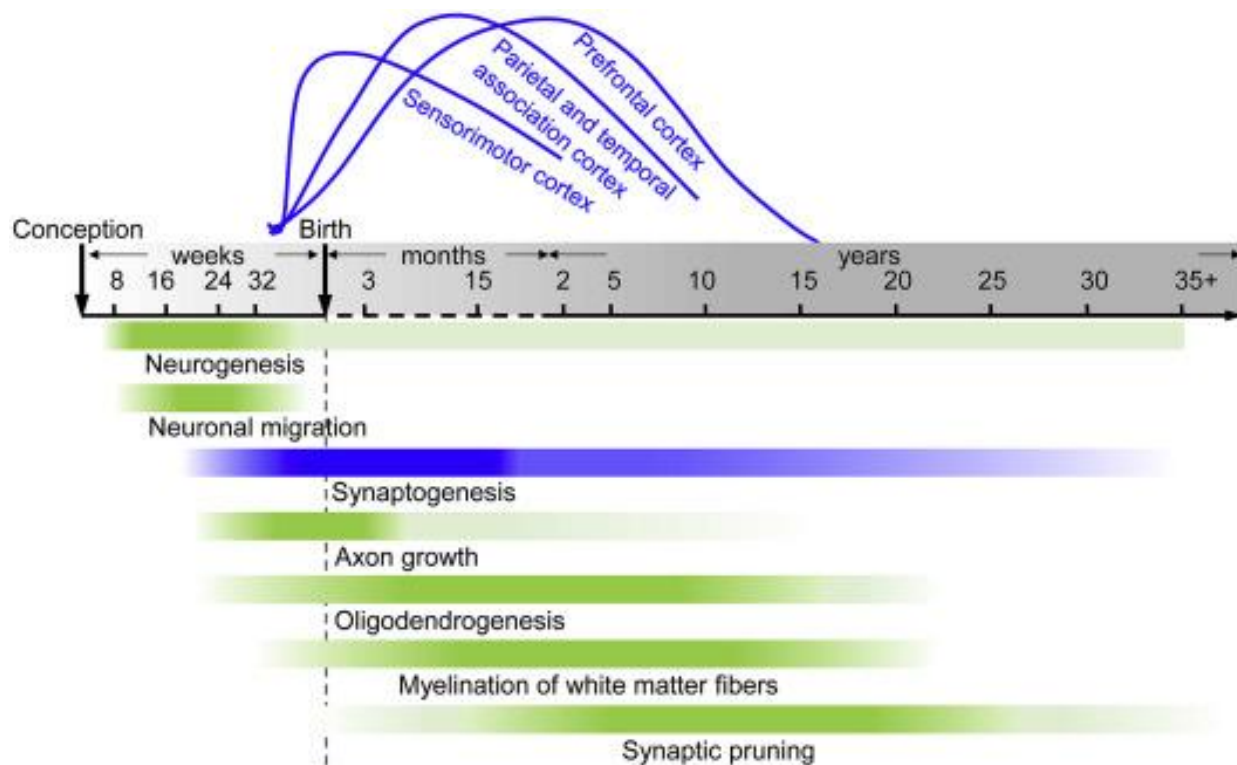


FIGURE 34.3 The importance of myelination in cognitive development. Myelination in different brain regions develops differently. (After Casey et al. 2005.)

Purves et al., (2018), p. 771

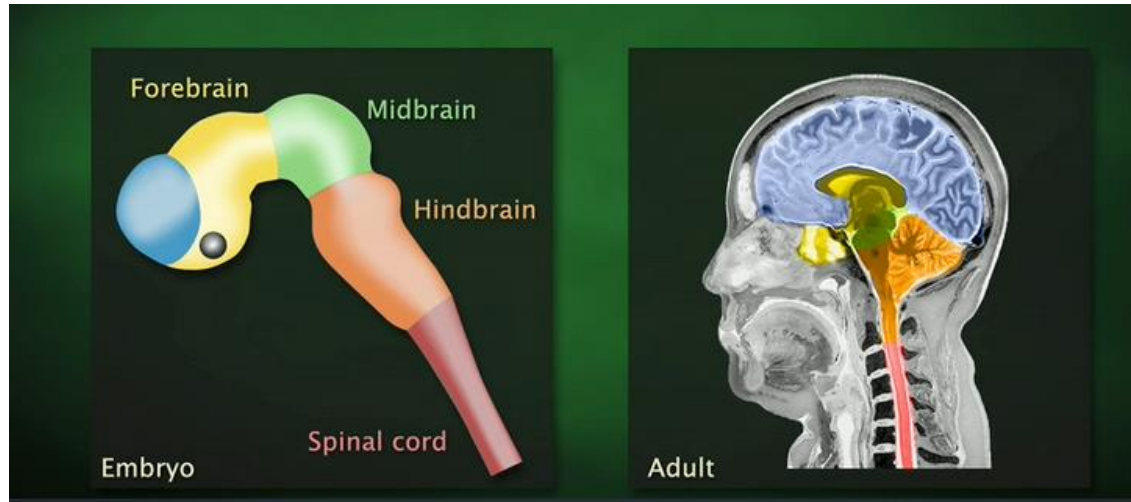
Throughout development => large number of synaptic connections. Synapses are strengthened and preserved when they are utilized, while weak or inefficient synapses are eliminated through a process called **pruning**. The process of synaptic refinement, which involves both synaptogenesis and pruning, results in neural computations that are efficient and adapted to the environment.



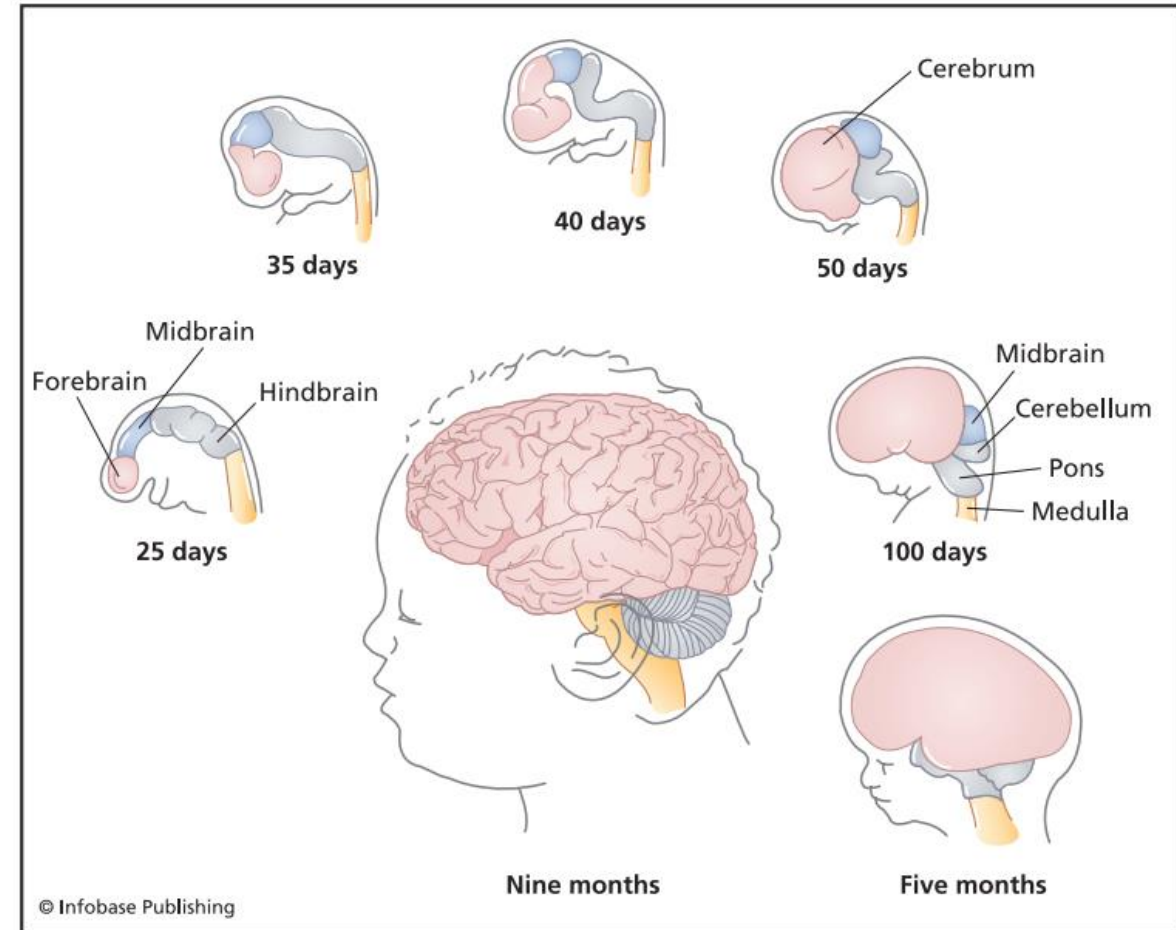
<https://tinyurl.com/5y77wp4h>

Synaptogenesis and pruning => throughout life => new learning and updating of older memories. However, superimposed on such local events are significant waves of synaptic pruning that are spatially specific and developmentally timed. The last such wave in human brain maturation occurs during adolescence and early adulthood, with pruning in **the temporal and prefrontal association cortex**. This late wave of pruning is followed by **myelination** of many axons in these areas of cortex.

Neural differentiation

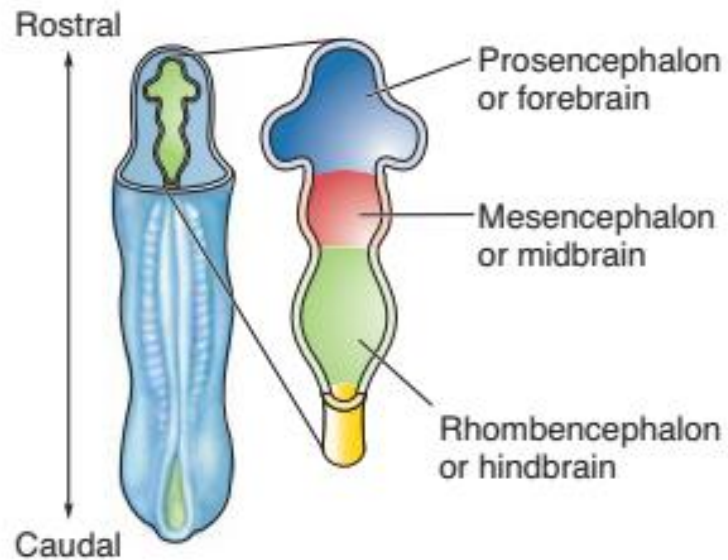


<https://media.hhmi.org/hl/08Lect2.html>



Bangalore, (2007), p. 26

Primary brain vesicles



▲ FIGURE 7.11

The three primary brain vesicles. The rostral end of the neural tube differentiates to form the three vesicles that will give rise to the entire brain. This view is from above, and the vesicles have been cut horizontally so that we can see the inside of the neural tube.

Bear et al., (2015), p. 195

prosencephalon (forebrain)

*the **most anterior** (rostral) part of the neural tube*

from Greek:

“prósō” = “forwards, onwards”

“enképhalos” = “brain”

mesencephalon (midbrain)

*the **middle** part of the neural tube*

from Greek:

“mésos” = “middle”

“enképhalos” = “brain”

rhombencephalon (hindbrain)

*the **most posterior** (caudal) part of the neural tube*

from Greek:

“rhómbos” = “rhombus”

“enképhalos” = “brain”

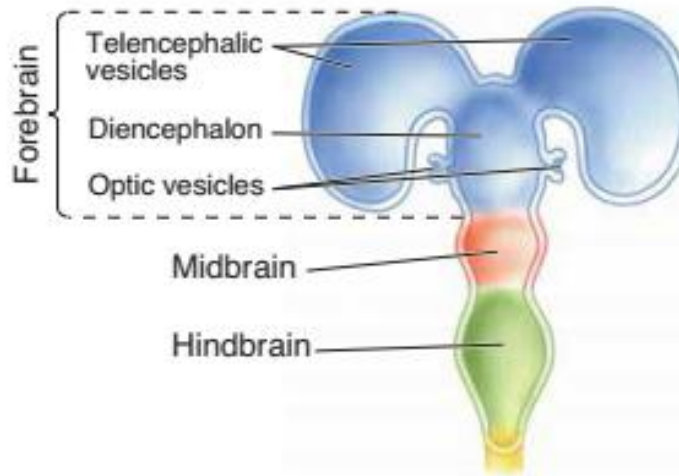
Forebrain

The **central** structure: **diencephalon**

diencephalon

middle part of the forebrain developing into the epithalamus, **thalamus**, **hypothalamus**, ventral thalamus and the **third ventricle**

from Greek: “dia-” = “through”; “enképhalos” = “brain”



▲ **FIGURE 7.12**
The secondary brain vesicles of the forebrain. The forebrain differentiates into the paired telencephalic and optic vesicles, and the diencephalon. The optic vesicles develop into the eyes.

Bear et al., (2015), p. 196

The **secondary vesicles**:

(1) the **optic** vesicles

=> optic nerve and retinas

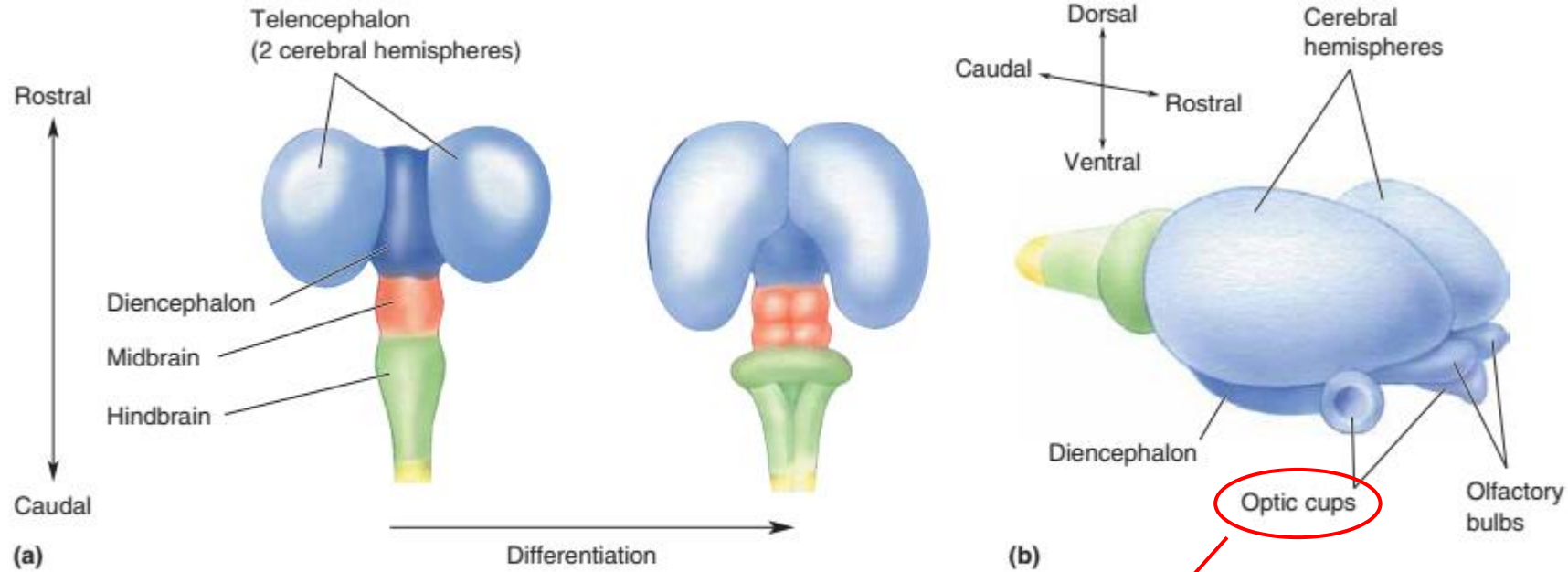
(2) the **telencephalic** vesicles

=> **telencephalon**

telencephalon

most anterior part of the forebrain, and the **last** subdivision of the brain to develop in the human embryo; it develops into the **cerebral hemispheres**

from Greek: “telos” = “end”; “enképhalos” = “brain”



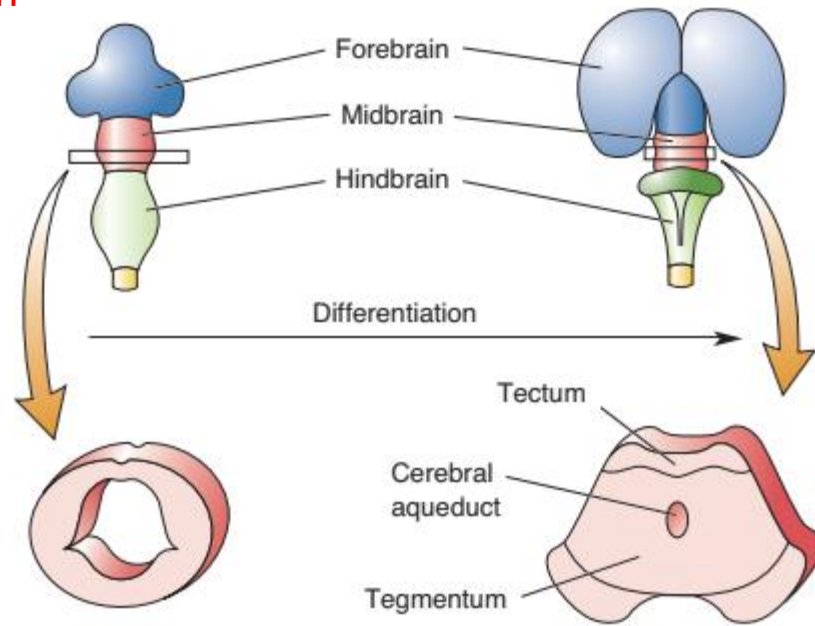
▲ **FIGURE 7.14**

Differentiation of the telencephalon. (a) As development proceeds, the cerebral hemispheres swell and grow posteriorly and laterally to envelop the diencephalon. (b) The olfactory bulbs sprout off the ventral surfaces of each telencephalic vesicle.

Bear et al., (2015), p. 196

*optic cups are part of the diencephalon that give rise to the **retinae** of the eyes*

Midbrain



▲ FIGURE 7.17

Differentiation of the midbrain. The midbrain differentiates into the tectum and the tegmentum. The CSF-filled space at the core of the midbrain is the cerebral aqueduct. (Drawings are not to scale.)

Bear et al., (2015), p. 199

tectum

formed from the **dorsal** surface of the mesencephalic vesicle;

gives rise to the **superior and inferior colliculi**

from Latin: “roof”

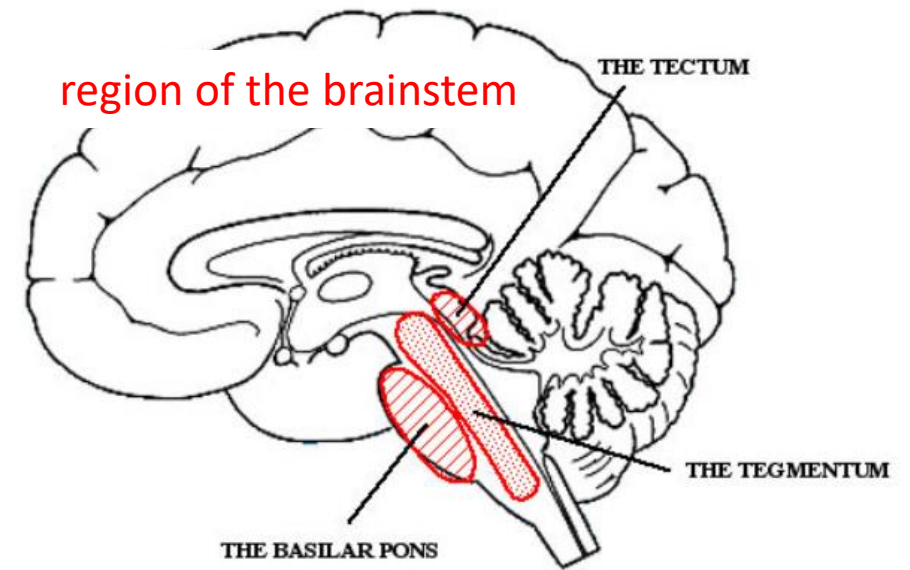
tegmentum

the **floor** of the midbrain;

most of the ascending **sensory** and descending

motor pathways of the brain pass through this region

from Latin: “covering”



http://www.pixelatedbrain.com/Mod_02/section_5.htm

*The **superior colliculus** receives input from the retina and the **visual cortex**

The **inferior colliculus** is involved in **auditory processing**

Practice midbrain nuclei at your own leisure

Midbrain Diagram (tectum and tegmentum)

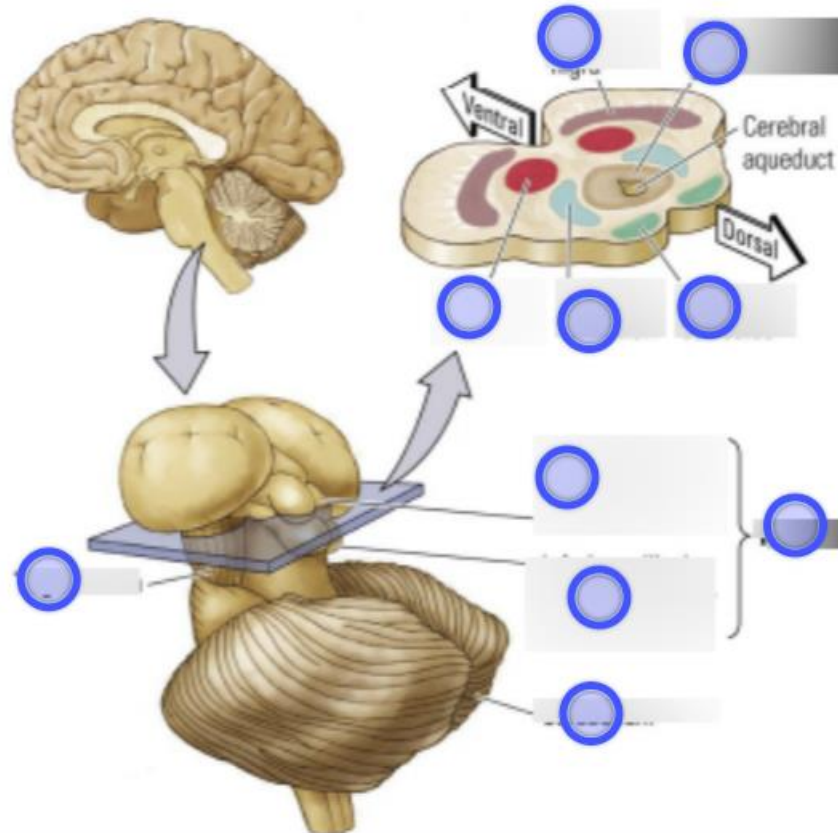
Flashcards

Learn

Test

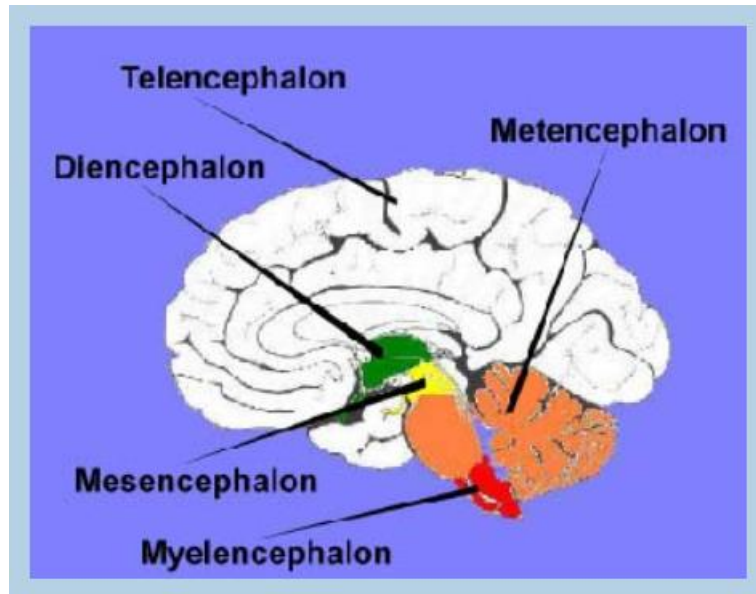
Match

Q-Chat



<https://quizlet.com/ca/264548434/midbrain-diagram-tectum-and-tegmentum-diagram/>

Hindbrain



<https://www.ruf.rice.edu/~lmgbrain/cglidden/>

The **hindbrain vesicle**:

- (a) **metencephalon** => pons and cerebellum;
- (b) **myelencephalon** => medulla.

metencephalon

from Greek: “meta” = “beyond, behind”; “enképhalos” = “brain”

=> **pons**

located on the brain stem's ventral surface; a “bridge” to the cerebellum;
transfers sensory information and motor impulses to and from the face.

from Latin: “bridge”

=> **cerebellum**

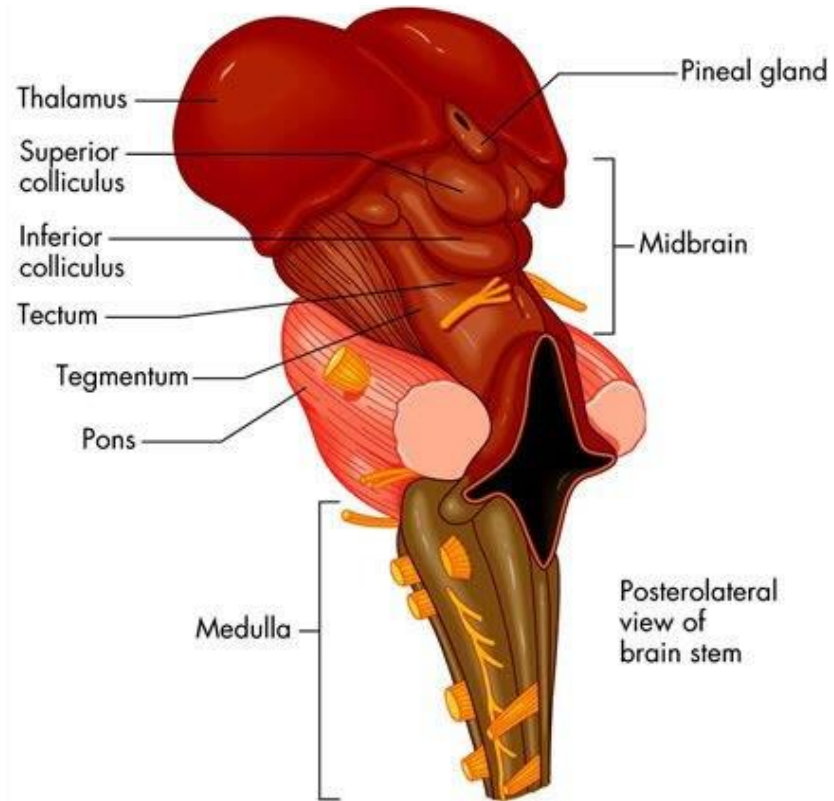
motor, sensory, and much more

myelencephalon (medulla)

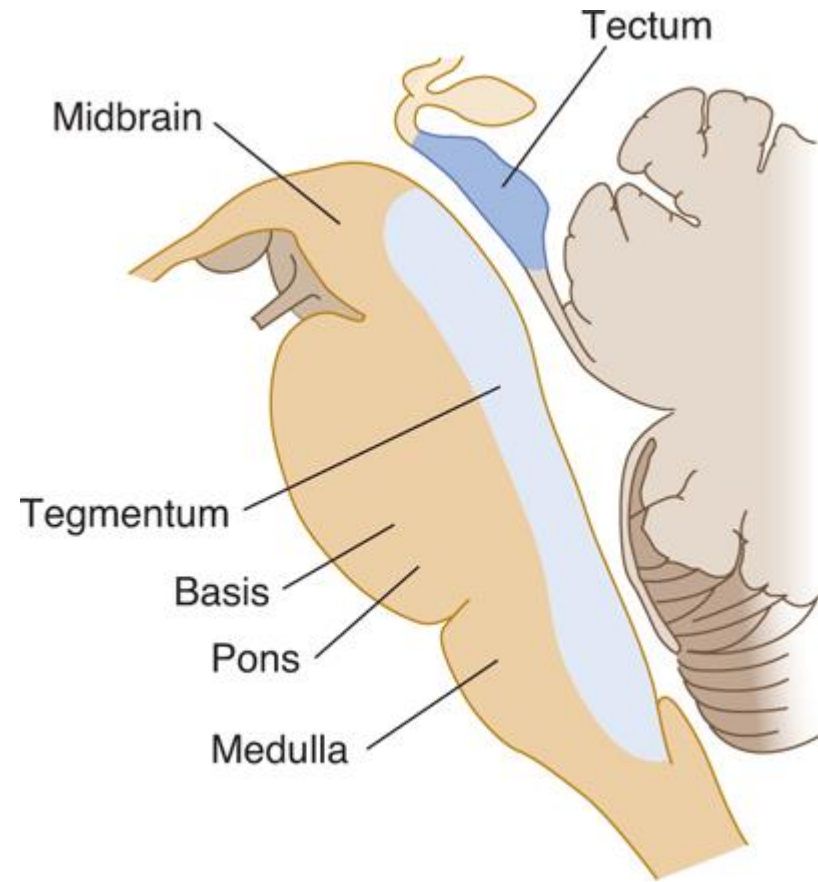
posterior portion of the brain stem; composed largely of tracts carrying
signals between the rest of the brain and the body.

from Greek: “myelos” = “marrow”; “enképhalos” = “brain”

Midbrain and hindbrain: combined view

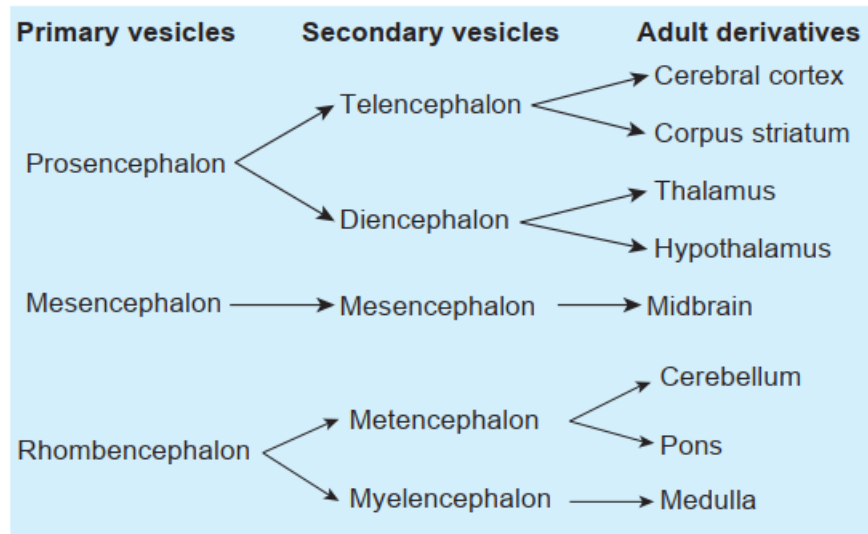


<https://tinyurl.com/yc7ctsc2>



<https://neupsykey.com/the-brain-stem-and-cerebellum-2/>

Summary



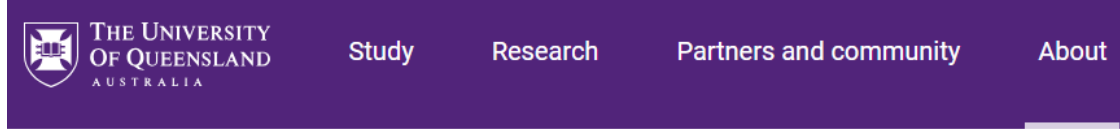
Mtui et al., (2021), p. 2

FIGURE A2 Representative relationships between the embryonic and adult forms of the central nervous system. See Chapter 22 for an account of brain development that more fully explains the formation of regional identity in the developing CNS, including the origin of the ventricular spaces.

Embryonic brain	Adult brain derivatives	Associated ventricular space
Prosencephalon (forebrain)	Telencephalon	Cerebral cortex Cerebral nuclei (basal ganglia, amygdala, basal forebrain)
	Diencephalon	Thalamus Hypothalamus Retina
Mesencephalon (midbrain)	Superior and inferior colliculi Red nucleus Substantia nigra	Cerebral aqueduct
Rhombencephalon (hindbrain)	Metencephalon	Cerebellum Pons
	Myelencephalon	Medulla oblongata
Spinal cord	Spinal cord	Central canal

Purves et al., (2018), Appendix

Further reading



Queensland Brain Institute

Adult neurogenesis

🏠 / The Brain / Brain functions

[Neurogenesis](#) occurs during embryonic development, and also in parts of the adult brain following birth.

This process, known as **adult neurogenesis**, was first [recognised in the 1960s](#), although it took until the 1990s for the field as a whole to accept that neurogenesis in adult animals could play a substantial role in brain function. Integral to this realisation was the discovery in 1992 by Professors [Perry Bartlett](#) and [Linda Richards](#) that the adult mouse brain contains neural stem cells. Because stem cells can divide, and differentiate into many types of cells, their discovery in adult brains suggested that neurogenesis could hold the key to treating neurodegenerative conditions such as Alzheimer's disease. Since then, neurogenesis has also been found to occur in the [hippocampi](#) of adult humans, and more recently is has been [confirmed to occur in the amygdala](#).

<https://qbi.uq.edu.au/brain-basics/brain-physiology/adult-neurogenesis>

Further resources



SPENCER S. ECCLES
HEALTH SCIENCES
LIBRARY
UNIVERSITY OF UTAH

Digital Publishing

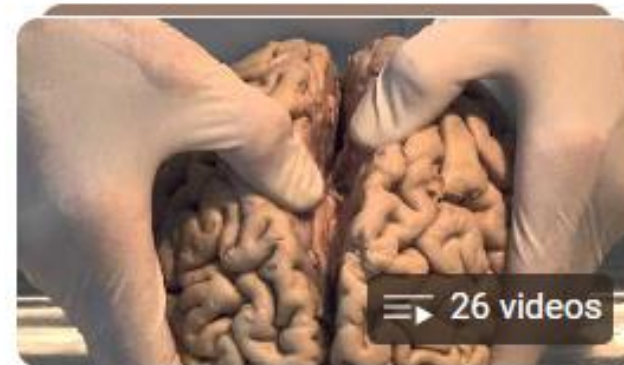

Eccles Health Sciences Library Digital Publishing

@EHSLDigitalPublishing · 205K subscribers · 525 videos

More about this channel >

library.med.utah.edu/publishing



Brain Anatomy for Health
Professionals

[View full playlist](#)

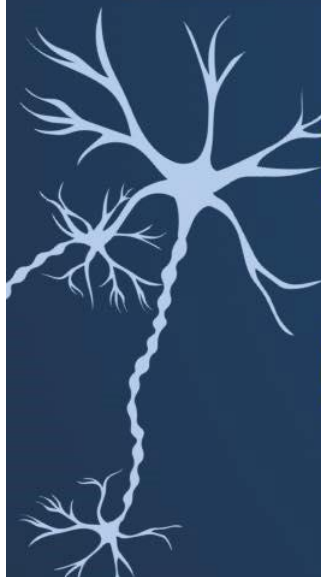<https://www.youtube.com/@EHSLDigitalPublishing/featured>



Vineri, ora 18:00
Live pe
DISCUȚIE PANEL



CUM ARATĂ O CARIERĂ ÎN NEUROȘTIINȚĂ?



LAVINIA CARMEN USCĂȚESCU
Incoming Research Assistant Professor,
Virginia Tech, SUA



ELENA ZAMFIR
Postdoctoral Researcher
Champalimaud Foundation, Portugalia



BAYAR MENZAT
Postdoctoral Researcher
Technische Universität Wien, Austria



OANA GURĂU
Doctor în Neuroștiințe
University of Oxford
Marea Britanie

Organizator:
ROMANIAN SCIENCE FESTIVAL

